

HYPNOZOITES OF *Cystoisospora* FRENKEL, 1977 (APICOMPLEXA: CYSTOISOSPORINAE) IN MONGOLIAN GERBIL LYMPH NODES AND THEIR TRANSMISSION TO CATS FREE OF COCCIDIA*

FRANCISCO CARLOS R. DE OLIVEIRA¹; CRISTIANE DA S. STABENOW²; FABIANA V. MASSAD³; CARLOS WILSON G. LOPES⁴

ABSTRACT:- OLIVEIRA, F.R. DE; STABENOW, C. DA S.; MASSAD, F.V.; LOPES, C.W.G. **Hypnozoites of *Cystoisospora* Frankel, 1977 (Apicomplexa: Cystoisosporinae) in Mongolian gerbil lymph nodes and their transmission to cats free of coccidia.** [Hipnozoítas de *Cystoisospora* Frenkel, 1977 (Apicomplexa: Cystoisosporinae) em linfonodos de gebil da Mongólia e suas transmissões para gatos livres de coccidia]. *Revista Brasileira de Parasitologia Veterinária*, v. 16, n. 2, p. 72-76, 2007. Laboratório de Sanidade Animal, Centro de Ciências e Tecnologias Agropecuárias, Universidade Estadual do Norte Fluminense Darcy Ribeiro. Av. Alberto Lamego, 2000, Campos dos Goytacazes, RJ. 28013-600, Brazil. E-mail: foliveira@uenf.br

Nine Mongolian gerbils (*Meriones unguiculatus*) were fed with 5.6×10^5 *Cystoisospora* sporulated oocysts orally. After 28 days post inoculation (DPI) four animals were euthanized, and their mesenteric lymph nodes were removed and they were submitted to peptic digestion technique and samples of them were submitted to transmission electron microscopy for hypnozoites identification. From lymph nodes digestion 4×10^2 hypnozoites/mL were obtained. Morphologically they were banana or stick form in shape, and measured 18.17 (15.09-20.02) in length by 6.21 (5.48-7.06) μm in width. In the same experiment, at 6 DAI, five gerbils were posted and liver, mesenteric lymph nodes and spleen were removed from each animal and were homogenized before given to three cats free of coccidia. All viscera used individually in each cat were capable to induce infection of species, *C. felis* and *C. rivolta*.

KEY WORDS: *Cystoisospora felis*, *C. rivolta*, experimental infection, *Meriones unguiculatus*.

RESUMO

Nove gerbils da Mongólia (*Meriones unguiculatus*) foram oralmente inoculados com $5,6 \times 10^5$ oocistos esporulados de *Cystoisospora*. Após 28 dias da infecção (DAI) quatro animais foram eutanasiados e parte de seus linfonodos mesentéricos foram usados para microscopia eletrônica de

transmissão para a observação de hipnozoítas e o restante submetido à digestão péptica. Da digestão dos linfonodos mesentéricos foram obtidos 4×10^2 hipnozoítas/ml. Estes foram morfológicamente semelhantes à forma de banana ou de clava medindo 18,17 (15,09-20,02) de comprimento por 6,21 μm (5,48-7,06) de largura. No mesmo experimento aos seis DAI outros cinco gerbils foram necropsiados e seus fígados, linfonodos mesentéricos e baços foram removidos e homogeneizados. Três gatos livres de coccidia, cada um deles alimentado com um tipo de víscera, eliminaram em suas fezes oocistos de *C. felis* e de *C. rivolta*.

PALAVRAS-CHAVE: *Cystoisospora felis*, *C. rivolta*, infecção experimental, *Meriones unguiculatus*.

INTRODUCTION

Hypnozoites of *Cystoisospora* had been already isolated in viscera of mice, rats, dogs, birds, bovines (FRANKEL;

* Sob os auspícios da FAPERJ/UENF.

¹ Laboratório de Sanidade Animal, Centro de Ciências e Tecnologia Agropecuárias (CCTA), Universidade Estadual do Norte Fluminense Darcy Ribeiro (UENF), Av. Roberto Lamego, 2000, Campos dos Goytacazes, RJ 28013-600. E-mail foliveira@uenf.br

² Curso de Pós-Graduação em Produção Animal, CCTA, UENF e Bolsista da FAPERJ. E-mail stabenow@uenf.br

³ Curso de Pós-Graduação em Ciências Veterinárias, Universidade Federal Rural do Rio de Janeiro (UFRRJ) e bolsista da CAPES. E-mail fvmassad@yahoo.com.br

⁴ Departamento de Parasitologia Animal e bolsista do CNPq, Instituto de Veterinária, UFRRJ, Km 07 da BR 465, Seropédica, RJ, 23890-000. E-mail lopescw@ufrrj.br

DUBEY, 1972; LINDSAY; BLAGBURN, 1994) guinea pig (HERZOG et al., 1993), rabbits (COSTA; LOPES, 1994), swine (CARVALHO-FILHO et al., 2001) and chicks (MASSAD et al., 2003).

The systemic distribution of hypnozoites in the different viscera evaluated in the intermediated hosts suggests a tropism more accentuated by mesenteric lymph nodes, spleen, liver and Payer's patches (FRENKEL; DUBEY, 1972; BRÖSIGKE et al., 1982; FREIRE; LOPES, 1996). However, Dubey (1979) observed that the skeletal muscles of mice inoculated with 10^5 and 10^6 sporocysts of *C. rivolta* were capable to determine infection in cats free of coccidia by shed oocysts of this parasite in their feces. Despite of this, the author no identified any forms of this parasite in the musculature through histology or visceral in print. However, Costa and Lopes (1998) using peptic digestion (PD) in tissues from rabbits experimentally infected with *C. felis* sporulated oocysts, indicated the presence of hypnozoites in liver, spleen, mesenteric lymph nodes and Payer's patches, without identifying them in the skeletal musculature.

The Mongolian gerbil has not spread out in the scientific community; however, this animal is considered an experimental model to many biological studies because of its physical, metabolic, psychosocial, biochemical and neurological characteristics (MARSTON, 1972; BURKE, 1979; RAYHURN; DOUGLAS, 1984; FRAZÃO-TEIXEIRA et al., 2002).

The objective of this research was to isolate hypnozoites of *Cystoisospora* in mesenteric lymph nodes of Mongolian gerbils (*Meriones unguiculatus*), identified through Transmission Electronic microscopy, and to infect coccidia free cats with viscera of previously infected gerbils to determine the susceptibility and distribution of *Cystoisospora* species.

MATERIAL AND METHODS

Sporulated oocysts of *Cystoisospora* were obtained from feces of three cats naturally infected at Centre for Zoonosis Control (CCZ) in the City of Campos dos Goytacazes, State of Rio de Janeiro, Brazil. They were concentrated by sugar saturated solution and stored in sulphuric acid solution at 2% in distilled water, ten times the volume of oocysts. Oocysts sporulation was completely at 74 hours by using an aquarium air pump.

An aliquot of oocysts suspension, concentrated and washed in phosphate-buffered saline (PBS) to remove sulphuric acid was counted at Neubauer chamber, and inoculum was determined in way each gerbil received orally 1 mL of suspension containing 5.6×10^5 sporulated oocysts of that 96 of *C. felis* and 4% of *C. rivolta*.

A total of nine Mongolian gerbils, were infected and maintained in individual cages. All animals received water and food *ad libitum* during the experiment.

In the 28th DAI four animals were euthanized in CO₂

saturated chamber in accordance to COBEA (2007). After that, animals were posted and mesenteric lymph nodes were removed. Samples of them were used for transmission electron microscopy (TEM) and remaining material was grinded and submitted to peptic digestion (PD) in accordance with Oliveira et al. (2001).

The number of hypnozoites of each lymph node was established according to methodology described for *C. rivolta* by Brösigke et al. (1982) and modified by Oliveira et al. (2001).

Hypnozoites, previously fixed in 2% glutaraldehyde (GA) solution, were measured by using a micrometric ocular K-15X on a light binocular microscope.

To the TEM, fragments of mesenteric lymph nodes were placed in 2 mL micro tubes containing Para formaldehyde at 4%, GA at 2.5%, cacodylate buffer 0.1 M, washed in PBS pH 7.0, and post fixed with osmium tetroxid and potassium Ferric cyanide. For dehydration was used acetone at 30, 50, 70, 90 and 100% at 20 minutes in each concentration. After that, mesenteric lymph nodes fragments were placed at Epon II in progressive concentrations in acetone at 100% (1:3, 1:2, 1:1 and 2:1) followed in pure Epon II for seven hours. Fragments were enclosed in resin, cut in ultra microtome at 50 µm in thickness and they were observed in TEM 900-Zeiss microscope after using uranile acetate and lead citrate for contrast.

Thirty six DAI, the remained gerbils were posted and liver, spleen and mesenteric lymph nodes were removed from each animal.

Three six week old cats, free of coccidia, were fed individually on grinded liver, spleen and mesenteric lymph nodes respectively.

Fecal samples taken daily from each cat was divided in two parts. The first was used for oocysts counts per grams of feces (OLIVEIRA et al., 2001), and to determine pre patent (PPP), and patent (PP) periods. The second one was used to allowed oocysts to sporulate as previously described. Length and width of sporulated oocysts besides morphology were also used to determine which species were involved in this infection.

RESULTS AND DISCUSSION

Cystoisospora oocysts from feces of naturally infect cats had ellipsoidal appearance in a piriform shape or spherical format range from 18.39 to 33.35 by 14.41 to 24.11 µm in diameters. Based on morph metric values of sporulated oocysts they were proportionally divided in 96 and 4% of *C. felis* and *C. rivolta* respectively. Great variability at oocysts dimensions were also observed by Rocha and Lopes (1971) and their morphological differences described by Dubey and Mehlhorn (1998).

The use of GA facilitated identification and measurements of hypnozoites recovered from mesenteric lymph nodes by hindering their movements and maintained the original shape of tissue stages (COSTA; LOPES, 1994; OLIVEIRA et al.,

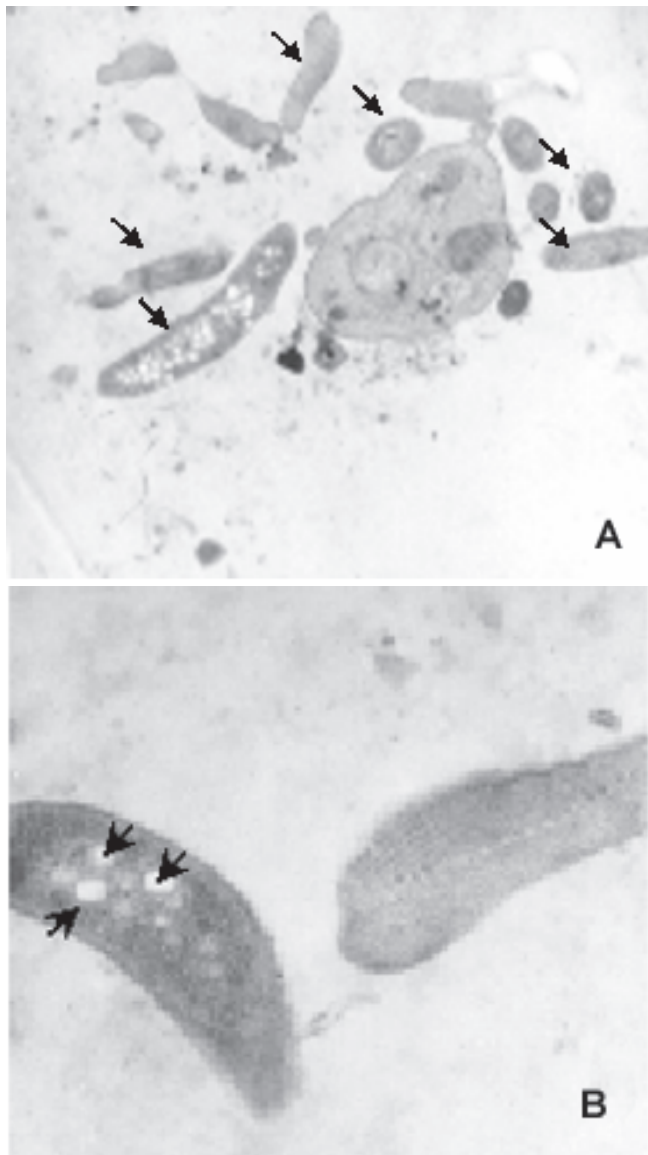


Figure 1. Gerbil mesenteric lymph node: A. Various *Cystoisospora* hypnozoites (→) near a mononuclear cell, 7000X. B. Amilopectin granules (→) in a *Cystoisospora* hypnozoites. 150000X. MET.

2001) and also confirmed by TEM (Figure 1). The isolation of the parasites confirmed the gerbil as intermediated host of same *Cystoisospora* species originated from felines (CARVALHO-FILHO et al., 2004) and mesenteric lymph nodes besides liver and spleen were considered as predilection site of *Cystoisospora* species in other species of animals (FRANKEL; DUBEY, 1972; COSTA; LOPES, 1994; OLIVEIRA et al., 2001).

The number of hypnozoites recovered in the gerbil mesenteric lymph nodes through PD was $4.0 \times 10^2/\text{mL}$ of suspension. This higher number of recovered hypnozoites from gerbils in relation to mice (FREIRE; LOPES, 1996) and rabbits (COSTA; LOPES, 1998) indicated that gerbils were more sensitive and had smaller capacity of eliminating these parasites in their tissues. Reinforces this inference

the observation of the parasite through TEM (Figure 1) in this experiment, since the difficulties in the hypnozoites observation in other hosts through PD (FRENKEL; DUBEY, 1972; HERZOG et al., 1993; LINDSAY; BLAGBURN, 1994; COSTA; LOPES, 1998, OLIVEIRA et al., 2001) or in histological section (COSTA et al., 2001; MASSAD et al., 2002). In spite of accentuated morphological differences (Figure 1) were impossible to determine what species should be corresponded the observed hypnozoites.

All gerbil viscera used in this study were capable to induce infection on cats free of coccidia which shed oocysts of *C. felis* and *C. rivolta* in their feces. The cat that fed on mesenteric lymph nodes had a PPP of three days and PP of 35 days, while the animal fed on liver, the PPP was four days and PP of 36 days of PP, the longest of the experiment. Regarding, the cat that fed on spleen PP was six days, similar data was observed by Frankel and Dubey (1972); however, PP was briefly, four days only. Dubey and Streitl (1976) observed that PPP of *C. rivolta* did not modify when different inocula were offered to cats free of coccidia, directly through sporulated oocysts or indirectly through ingestion of mice tissues infected previously with the same amount of sporulated oocysts, but in the same work, *C. felis* did not demonstrate the same behavior because of its PPP that went long for cats inoculated with mice tissues. This results match with the biological cycle of the genus *Cystoisospora* described by Dubey (1992) that affirmed “when the appropriate definitive host eats the infected herbivore, or infected carnivore that is not the definitive host, the encysted hypnozoites are liberated of the tissues through digestion and begin an infection cycle with smaller PPP”.

The amount of shedding oocysts was not proportional to the amount of inoculum, because after the gerbils' inoculation and subsequent infection of the cats free of coccidia the percentage of *C. rivolta* was 3.5 times more than the inoculated amount as observed by Oliveira et al. (2001; 2002) and Mello et al. (2003) and indirectly by this work where oocysts shed by cats, both coccidia had more tropism to the mesenteric lymph nodes than for the liver. *Cystoisospora rivolta* in spite of being eliminated in small quantities of oocysts was more competitive than *C. felis*.

CONCLUSIONS

Mongolian gerbils (*Meriones unguiculatus*) was considered as intermediated host for *C. felis* and *C. rivolta* and both parasites had more tropism to mesenteric lymph nodes than to liver and spleen. *Cystoisospora rivolta* had better successful to establish than *C. felis* in cats fed on viscera of chronically infected gerbils.

REFERENCES

BRÖSIGKE, S., HEINE, J.; BOCH, J. Der nachweis

- extraintestinalen entwicklungsstadien (dermozoiten) in extraintestinal mit *Cystoisospora rivolta* oozysten infizierten mausen. *Klontier Praxis*, v. 27, n. 1, p. 25-34, 1982.
- BURKE, T.J. Rats, mice hamsters and gerbils. *Veterinary Clinics of North America/Small Animal Practice*, v. 9, n. 3, p. 473-486, 1979.
- CARVALHO-FILHO, P.R. DE; MASSAD, F.V.; BEZERRA, M.M.; OLIVEIRA, F.C.R. de; LOPES, C.W.G. *Cystoisospora felis* e *C. rivolta* (Apicomplexa: Cystoisosporinae) em vísceras de gerbils da Mongólia (*Meriones unguiculatus*) e sua transmissão para gatos livres de coccídios. *Revista Brasileira de Parasitologia Veterinária*, v. 13, n. 4, p. 169-172, 2004.
- CARVALHO-FILHO, P.R. DE; MELO, P.S.; LOPES, C.W.G. Infecção experimental de felinos com vísceras de suíno infectado com oocistos de *Cystoisospora felis* (Apicomplexa: Cystoisosporinae). *Anais de Iniciação Científica da UFRRJ*, v. 11, n. 1, p. 337-338, 2001.
- COBEA, Legislação & ética. Disponível on: < <http://www.cobea.org.br/ética.htm>>. Access: 14 Mar 2007.
- COSTA, P.S. DA; LOPES, C.W.G. Avaliação do parasitismo por *Cystoisospora felis* (Wenyon, 1923) Frenkel, 1977 (Apicomplexa: Cystoisosporinae) em coelhos tipo carne. *Revista Brasileira de Parasitologia Veterinária*, v. 7, n. 1, p. 15-19, 1998.
- COSTA, P.S. DA; LOPES, C.W.G. Hipnozoítas de *Cystoisospora felis* (Apicomplexa: Cystoisosporinae). *Revista Brasileira de Ciência Veterinária*, v. 1, n. 1, p. 35-36, 1994.
- COSTA, P.S. DA; LOPES, C.W.G.; CARVALHO, E.C.Q. Patologia comparativa na infecção experimental por *Cystoisospora felis* (Apicomplexa: Cystoisosporinae) em coelhos tipo carne. *Revista Brasileira de Medicina Veterinária*, v. 23, n. 5, p. 215-218, 2001.
- DUBEY, J.P. Life cycle of *Isospora rivolta* (Grassi, 1897) in cats and mice. *Journal of Protozoology*, v.26, n. 3, p. 433-442, 1979.
- DUBEY, J.P. *Toxoplasma, Hammondia, Besnoitia, Sarcocystis* and other tissue cyst-forming coccidia of man and animals. In: KREIER, J. P., *Protozoa*. New York: Academic Press, 1992. v.6, p.120-128.
- DUBEY, J.P.; MEHLHORN, H. Extra intestinal stages of *Isospora ohioensis* from dogs in mice. *Journal of Parasitology*, v. 64, n. 6, p. 689- 695, 1978.
- DUBEY, J.P.; STREITEL, R.H. *Isospora felis* and *I. rivolta* infections in cats induced by mouse tissue or oocysts. *British Veterinary Journal*, v. 132, n. 6, p. 649-651. 1976.
- FRAZÃO-TEIXEIRA, E.; OLIVEIRA, F.C.R. de; ALMEIDA, E.S.C.; BAHIA-OLIVEIRA, L.M.G. Sensibilidade de *Meriones unguiculatus* (gerbil) e *Mus musculus* (camundongo) ao *Toxoplasma gondii* (Apicomplexa: Toxoplasmatinae) estudo comparativo. In. CONGRESSO BRASILEIRO DE PARASITOLOGIA VETERINÁRIA, 12, 2002, Rio de Janeiro. *Anais...* Rio de Janeiro: CBPV, 2002. p. 46-48.
- FREIRE, R.B.; LOPES, C.W.G. Distribuição de hipnozoítas de *Cystoisospora felis* (Wenyon, 1923) Frenkel, 1977 (Apicomplexa: Sarcocystidae) em camundongos albinos experimentalmente infectados. *Revista Brasileira de Parasitologia Veterinária*, v. 5, n. 1, p. 23-28, 1996.
- FRENKEL, J.K.; DUBEY, J.P. Rodents as vector for feline coccidia, *Isospora felis* and *Isospora rivolta*. *Journal of Infectious Diseases*, v. 125, n. 1, p. 69-72, 1972.
- HERZOG, J.D.; FLAUSINO, W.; FREIRE, R.B. Hipnozoítas de *Cystoisospora felis* em cobaio. In. SEMINÁRIO BRASILEIRO DE PARASITOLOGIA VETERINÁRIA, 8, 1993. *Resumos* Londrina: CBPV, 1993. p. 9.
- LINDSAY, D.S.; BLAGBURN, B.L. Biology of mammalian *Isospora*. *Parasitology Today*, v. 10, n. 6, p. 214-220, 1994.
- MARSTON, J.H. The Mongolian gerbil. In. HUME, C.W. *The UFAW handbook on the care and management of laboratory animals*. 4 ed. London: Churchill Livingstone, 1972. chap. 21, p. 257-268.
- MASSAD, F. V.; OLIVEIRA, F.C.R. de; ALBUQUERQUE, G. R.; LOPES, C. W. G. Hipnozoítas de *Cystoisospora ohioensis* (Dubey, 1975) Frenkel, 1977 (Apicomplexa: Cystoisosporinae) em frangos. *Revista Brasileira de Ciência Veterinária*, v.10, n.1, p.57-58, 2003.
- MASSAD, F.V.; REYES, S. OLIVEIRA, F.C.R.; LOPES, C.W.G. Avaliação das alterações clínicas, do ganho de peso e do peso das carcaças em frangos infectados com oocistos esporulados de *Cystoisospora ohioensis* (Apicomplexa: Cystoisosporinae) In. CONGRESSO BRASILEIRO DE PARASITOLOGIA VETERINÁRIA, 12.2002. Rio de Janeiro. *Anais ...* Rio de Janeiro: CBPV, 2002. 1 CD-Room
- MELO, P. S.; CARVALHO FILHO, P. R. DE; OLIVEIRA, F. C. R. DE; FLAUSINO, W.; LOPES, C. W. G. Hypnozoites of *Cystoisospora felis* (Wenyon, 1923) Frenkel, 1977 (Apicomplexa: Cystoisosporinae) in swine (*Sus scrofa domestica*) viscera: a new intermediated host. *Revista Brasileira de Parasitologia Veterinária*, v. 12, n. 3, p. 103-107, p. 2003.
- OLIVEIRA, F.C. R. DE; LOPES, C. W. G.; MASSAD, F. V.; MELO, P.S. Influência da infecção por *Cystoisospora ohioensis* (Dubey, 1975) Frenkel, 1977 no ganho de peso de camundongos albinos. *Revista Brasileira de Parasitologia Veterinária*, v. 11, n. 2, p. 103-107, 2002.
- OLIVEIRA, F.C.R. DE; ALBUQUERQUE, G.R.; LOPES, C.W.G.; MASSAD, F.V.; MUNHOZ, A.D. Hipnozoítas de *Cystoisospora ohioensis* (Dubey, 1975) Frenkel, 1977 (Apicomplexa: Cystoisosporinae) recuperados de órgãos de camundongos através da digestão péptica. *Revista Brasileira de Parasitologia Veterinária*, v. 10, n. 1, p. 29-35, 2001.
- RAYHURN, P.; DOUGLAS, J.B. Fatty acid synthesis in brown adipose tissue of the Mongolian gerbil (*Meriones unguiculatus*); influence of acclimation temperature on synthesis in brown adipose tissue and the liver in relation

to whole-body synthesis. *Comparative Biochemistry and Physiology. Part B: Biochemistry and Molecular Biology*, v. 78, n. 3, p. 601-607, 1984.

ROCHA, E.M.; LOPES, C.W.G. Comportamento da

Isospora canis, *Isospora felis* e *Isospora rivolta* em infecções experimentais em cães e gatos. *Arquivos da Universidade Federal Rural do Rio de Janeiro*, v. 1, n. 1, p. 8 -96, 1971.

Received on June 19, 2006.

Accepted for publication on March 13, 2007.