

RESEARCH NOTE

***Sarcocystis lindsayi*-LIKE (APICOMPLEXA: SARCOCYSTINAE) OF THE OPOSSUM (*Didelphis aurita*) FROM SOUTHEASTERN BRAZIL ***

CRISTIANE S. STABENOW¹; FRANCISCO C. R. DE OLIVEIRA²; GEORGE R. ALBUQUERQUE³; CARLOS WILSON G. LOPES⁴

ABSTRACT:- STABENOW, C.S.; OLIVEIRA, F.C.R. DE; ALBUQUERQUE, G.R.; LOPES, C.W.G. *Sarcocystis lindsayi*-like (Apicomplexa: Sarcocystinae) of the opossum (*Didelphis aurita*) from Southeastern Brazil. [*Sarcocystis lindsayi*-simile (Apicomplexa: Sarcocystinae) do gambá (*Didelphis aurita*) da região sudeste do Brasil]. *Revista Brasileira de Parasitologia Veterinária*, v. 17, supl. 1, p. 342-344, 2008. Laboratório de Sanidade Animal, Hospital Veterinário, Universidade Estadual do Norte Fluminense Darcy Ribeiro, Avenida Alberto Lamego, 2000, Campos dos Goytacazes, RJ 28013-602, Brasil. E-mail: foliveira@uenf.br

Sporocysts of *Sarcocystis* were obtained from intestinal scrapings of three out of five opossums (*Didelphis aurita*) trapped in the southeastern region, of the State of Rio de Janeiro, Brazil. Fifteen caged budgerigars (*Melopsittacus undulatus*) received, orally, twenty-six sporocysts in 500mL PBS, but only five belonging to one of the groups developed clinical signs, that consisted of anorexia, lethargy, ruffled feathers and dyspnoea, and parasitism in tissues. Two of the five budgerigars died on the 25th and 29th days after infection (DAI). The other three budgerigars were posted on the 30th DAI. In all the five infected birds were observed meronts in the capillaries of the lungs and cysts in muscles, mainly in the tongue and legs.

KEY WORDS: *Sarcocystis*, opossum, *Didelphis aurita*, budgerigar, *Melopsittacus undulatus*.

RESUMO

Esporocistos de *Sarcocystis* foram obtidos de raspado de intestino de três dentre cinco gambás (*Didelphis aurita*) capturados na região sudeste, no Estado do Rio de Janeiro, Brasil. Quinze periquitos australianos (*Melopsittacus undulatus*) receberam, via oral, vinte e seis esporocistos em 500ml de PBS, mas apenas cinco pertencentes a um dos grupos desenvolveram sinais clínicos, caracterizados por anorexia, letargia, pe-

nas arripiadas e dispnéia, e parasitismo tecidual. Dois dos periquitos vieram a óbito no 25º e 29º dias após infecção (DAI). Os outros três periquitos foram eutanasiados no 30º DAI. Em todos os cinco periquitos infectados foram observados merontes nos capilares pulmonares e cistos musculares, principalmente na língua e pernas.

PALAVRAS-CHAVE: *Sarcocystis*, gambá, *Didelphis aurita*, periquito australiano, *Melopsittacus undulatus*.

² Supported by FAPERJ and CNPq.

¹ Laboratório de Sanidade Animal (LSA), Centro de Ciências e Tecnologias Agropecuárias (CCTA), Universidade Estadual do Norte Fluminense Darcy Ribeiro (UENF), Campos dos Goytacazes, RJ, 28013-602, Brasil. E-mail: stabenow@uenf.br

² LSA, CCTA, UENF, Campos dos Goytacazes, RJ, Brasil. E-mail: foliveira@uenf.br - CNPq fellowship

³ Departamento de Ciências Agrárias e Ambientais, Universidade Estadual de Santa Cruz, Salobrinho, Ilhéus, BA 45662-000, Brasil. E-mail: gralbu@uesc.br

⁴ Departamento de Parasitologia Animal, Instituto de Veterinária, Universidade Federal Rural do Rio de Janeiro, Seropédica, RJ 23890-000, Brasil. E-mail: lopeswcg@ufrj.br - CNPq fellowship

Coccidia of the *Sarcocystis* genus were considered an obligatory heteroxenous parasite based on pray-predator life cycle (FAYER, 1980). In 1984 the North American opossum (*Didelphis virginiana*) was considered as the definitive host for *S. falcatula*, which has a great variety of bird species as its intermediate, and the budgerigar (*Melopsittacus undulatus*) was described as a good experimental intermediate host for the identification of *Sarcocystis* species that have birds as intermediate hosts and opossums as their definitive hosts (BOX et al., 1984). There are three species of opossum in Brazil: *D.*

albiventris which has white ears and can be found in Brazilian savannas, caatinga (tropical thorn forest) and pantanal; *D. aurita* which has black ears and mainly inhabits the Atlantic Rain Forest in southeastern Brazil; and *D. marsupialis* also with black ears and found mainly in the Amazon region (KALAFUT, 2005). *Didelphis albiventris* has been considered as the definitive host of *S. falcatula* in Argentina (DUBEY et al., 1999) as well as in Brazil for *S. falcatula-simile* (DUBEY et al., 2000), *S. neurona* (DUBEY et al., 2001a) and *S. lindsayi* (DUBEY et al., 2001b). *Sarcocystis lindsayi* is the species recently described as similar to *S. falcatula*, but its natural intermediate host and complete life cycle are not known (DUBEY et al., 2001b). In the life cycle of *S. falcatula* the opossum becomes infected eating muscular tissue of infected birds containing mature cysts and birds, which are intermediate hosts, become infected through the ingestion of sporocysts in contaminated food or water (BOX et al., 1984). This research had the objective to identify by morphological and biological procedures sporocysts of *Sarcocystis* found in *D. aurita* trapped in the Municipalities of Campos dos Goytacazes and Seropédica, both in the State of Rio de Janeiro.

Opossums were trapped under license #96/02-RJ, registered at IBAMA #02022.008098/02-91, in the State of Rio de Janeiro, being three in Seropédica and two in Campos dos Goytacazes. The animals were anesthetized and posted according to methodology described by Porter et al. (2001), and in accordance with the Brazilian legislation (ALERJ, 2002; CFMV, 2002). Sporocysts were obtained by scraping the intestinal mucosa according to Dubey et al. (1999) and Porter et al. (2001). Sporocysts were removed from the intestinal mucosa and stored at 4°C according to Dubey et al. (1999).

Only the three opossums from Seropédica were positive for sporocysts of *Sarcocystis* (Figure 1a) and the sporocysts were fed at the amount of 26 sporocysts in 500mL of PBS to three groups of five budgerigars. One group of budgerigars received saline solution (placebo). Clinical signs and parasitism were found in tissues only in the birds belonging to one group. Clinical signals consisted of anorexia, lethargy, ruffled feathers and dyspnoea. Two of the five budgerigars died at 25 and 29 DAI respectively. The last three budgerigars were posted at 30 DAI. The sporocysts obtained from *D. aurita* were on average 8,47 mm long by 5,68 mm wide, and were different in relation to those observed by Dubey et al. (2001b) for *S. lindsayi*, that were on average 12 mm long by 7 mm wide. Meronts were observed in all the five budgerigars in the inner layers the lung capillaries (Figure 1b), which was also reported for *S. falcatula* (SMITH et al., 1987) and for *S. lindsayi* (DUBEY et al., 2001b). The cysts observed in the budgerigar tissues were microscopic, ranging from 65,25 to 118,06 mm long by 13,98 to 29,38 mm wide. They were found in muscles from the chest, legs (Figure 1c), tongue and heart, in large numbers especially in skeletal muscle from the legs and tongue. The cysts from *S. falcatula* are also found in the skeletal and cardiac muscles in large numbers, but they can be macroscopic up to 9 mm long (NEILL et al., 1989), while the cysts from *S. lindsayi* are microscopic

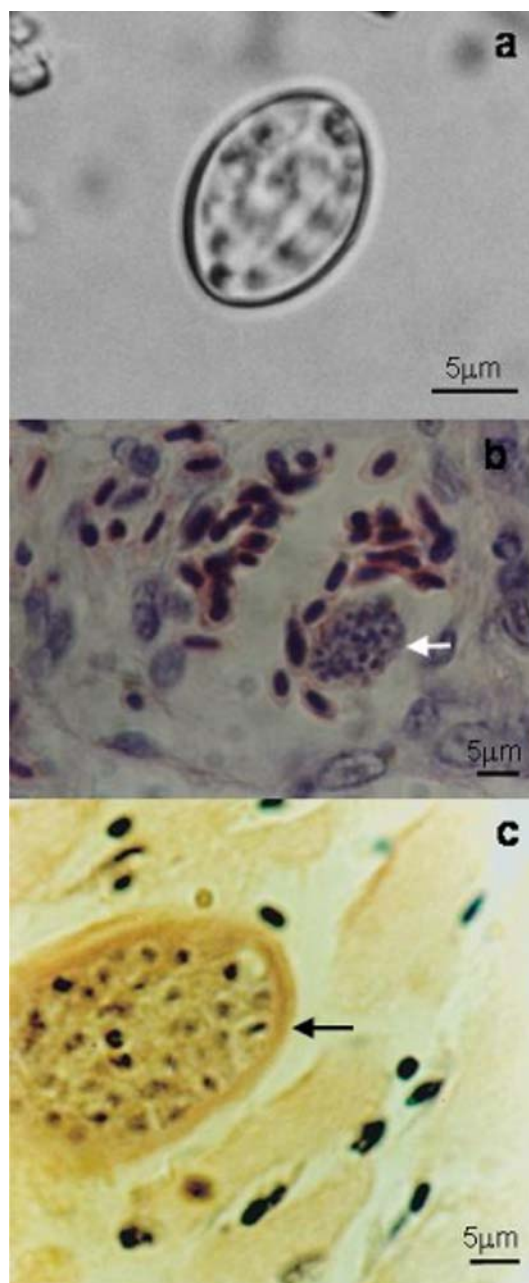


Figure 1. *Sarcocystis lindsayi*-like: a. Sporocyst from *Didelphis aurita*. Saturated sugar solution; b. Meront (⊗) in the inner layers of capillaries of lungs, H.E.; and c. Cyst (⊗) in the muscle of the leg, H.E., from an experimental infected budgerigar.

up to 600 mm long by 50 mm wide and found in small numbers only in legs (DUBEY et al., 2001b).

Although the sporocysts isolated in the opossum were slightly smaller, the parasite when inoculated in budgerigars and observed under optical microscopy on tissues had morphological characteristics similar to *S. lindsayi*. This permitted inference that this is the first report of a species of *Sarcocystis* in *D. aurita* which has birds such as intermediate host, and thus the parasite in question can be considered *S. lindsayi*-like and other research must be developed to characterize the species.

REFERENCES

- ALERJ. *Lei nº3900 de julho de 2002*. Available on: <<http://www.alerj.rj.gov.br/processo2.htm>>. Accessed in: Mar. 9, 2004.
- BOX, E.D.; MEIER, J.L.; SMITH, J.H. Description of *Sarcocystis falcatula* Stiles, 1893, a parasite of birds and opossums. *Journal of Protozoology*, v. 31, n. 4, p. 521-524, 1984.
- CFMV. *Resolução nº 714 de 20 de junho de 2002*. Available on: <<http://www.cfmv.org.br/res714.htm>>. Accessed in: Mar. 9, 2004.
- DUBEY, J.P.; LINDSAY, D.S.; KERBER, C.E.; KASAI, N.; PENA, H.F.J.; GENNARI, S.M.; KWOK, O.C.H.; SHEN, S.K.; ROSENTHAL, B.M. First isolation of *Sarcocystis neurona* from the South America opossum, *Didelphis albiventris*, from Brazil. *Veterinary Parasitology*, v. 95, n. 2-4, p. 295-304, 2001a.
- DUBEY, J.P.; LINDSAY, D.S.; REZENDE, P.C.B.; COSTA, A.J. Characterization of an unidentified *Sarcocystis falcatula*-like parasite from the South America opossum, *Didelphis albiventris* from Brazil. *Journal of Eukaryotic Microbiology*, v. 47, n. 6, p. 538-544, 2000.
- DUBEY, J.P.; ROSENTHAL, B.M.; SPEER, C.A. *Sarcocystis lindsayi* n. sp. (Protozoa: Sarcocystidae) from the South American opossum, *Didelphis albiventris* from Brazil. *Journal of Eukaryotic Microbiology*, v. 48, n. 5, p. 595-603, 2001b.
- DUBEY, J.P.; VENTURINI, L.; VENTURINI, C.; BASSO, W.; UNZAGA, J. Isolation of *Sarcocystis falcatula* from the South American opossum (*Didelphis albiventris*) from Argentina. *Veterinary Parasitology*, v. 86, n. 4, p. 239-244, 1999.
- FAYER, R. Epidemiology of protozoan infections: the Coccidia. *Veterinary Parasitology*, v. 6, n. 1-3, p. 75-103, 1980.
- KALAFUT, M. Genus *Didelphis*. Large american opossums. Available on: <<http://www.knowyoursto.com/didelphidae/didelphis.html>>. Accessed in: Dez. 1, 2005.
- NEILL, P.J.G.; SMITH, J.H.; BOX, E.D. Pathogenesis of *Sarcocystis falcatula* (Apicomplexa: Sarcocystidae) in the budgerigar (*Melopsittacus undulatus*). IV. Ultrastructure of developing, mature and degenerating sarcocysts. *Journal of Protozoology*, v. 36, n. 4, p. 430-437, 1989.
- PORTER, R.A.; GINN, P.E.; DAME, J.B.; GREINER, E.C. Evaluation of the shedding of *Sarcocystis falcatula* sporocysts in experimentally infected Virginia opossums (*Didelphis virginiana*). *Veterinary Parasitology*, v. 95, n. 2-4, p. 313-319, 2001.
- SMITH, J.H.; MEIER, J.L.; NEILL, P.J.G.; BOX, E.D. Pathogenesis of *Sarcocystis falcatula* in the budgerigar. I. Early pulmonary schizogony. *Laboratory Investigation*, v. 56, n. 1, p. 60-71, 1987.

Received on April 30, 2008.

Accepted for publication on September 14, 2008.