

Infestation by *Haematopinus quadripertusus* on cattle in São Domingos do Capim, state of Pará, Brazil

Infestação por *Haematopinus quadripertusus* em bovinos de São Domingos do Capim, estado do Pará, Brasil

Alessandra Scofield^{1*}; Karinny Ferreira Campos²; Aryane Maximina Melo da Silva³; Cairo Henrique Sousa Oliveira⁴; José Diomedes Barbosa³; Gustavo Góes-Cavalcante¹

¹Laboratório de Parasitologia Animal, Programa de Pós-graduação em Saúde Animal na Amazônia, Faculdade de Medicina Veterinária, Universidade Federal do Pará – UFPA, Castanhal, PA, Brasil

²Programa de Pós-graduação em Ciência Animal, Universidade Federal do Pará – UFPA, Belém, PA, Brasil

³Programa de Pós-graduação em Saúde Animal na Amazônia, Universidade Federal do Pará – UFPA, Castanhal, PA, Brasil

⁴Programa de Pós-graduação em Ciência Animal, Escola de Veterinária, Universidade Federal de Minas Gerais – UFMG, Belo Horizonte, MG, Brasil

Received September 15, 2011

Accepted March 20, 2012

Abstract

Severe infestation with lice was observed on crossbred cattle (*Bos taurus indicus* × *Bos taurus taurus*) in the municipality of São Domingos do Capim, state of Pará, Brazil. Sixty-five animals were inspected and the lice were manually collected, preserved in 70% alcohol and taken to the Animal Parasitology Laboratory, School of Veterinary Medicine, Federal University of Pará, Brazil, for identification. The adult lice were identified as *Haematopinus quadripertusus*, and all the cattle examined were infested by at least one development stage of this ectoparasite. The specimens collected were located only on the tail in 80% (52/65) of the cattle, while they were around the eyes as well as on the ears and tail in 20% (13/65). Nits, nymphs and adults of the parasite were respectively collected from 98.46% (64/65), 38.46% (25/65) and 23.08% (15/65) of the animals examined. This is the first report of bovine pediculosis caused by *H. quadripertusus* in the state of Pará, Brazil. Further studies should be conducted to determine the occurrence pattern of this species in Brazil and its importance to livestock production.

Keywords: Pediculosis, *Haematopinus quadripertusus*, bovines, lice, Phthiraptera, Pará, Brazil.

Resumo

Alta infestação por piolhos foi observada em vacas mestiças *Bos taurus indicus* e *Bos taurus taurus* do município de São Domingos do Capim, Estado do Pará, Brasil. Sessenta e cinco animais foram inspecionados e os piolhos foram coletados manualmente, armazenados em álcool 70% e transportados ao Laboratório de Parasitologia Animal da Faculdade de Medicina Veterinária da Universidade Federal do Pará para a identificação. Os exemplares adultos foram identificados como *Haematopinus quadripertusus* e todos os animais examinados apresentaram pelo menos um estágio de desenvolvimento do ectoparasito. Em 80% (52/65) dos animais, os exemplares coletados localizavam-se somente na cauda e em 20% (13/65) na região periocular, orelha e cauda. Lêndeas, ninfas e adultos foram coletados, respectivamente, em 98,46% (64/65), em 38,46% (25/65) e em 23,08% (15/65) dos animais examinados. Esse é o primeiro relato de pediculose bovina causada por *H. quadripertusus* no estado do Pará e mais estudos devem ser realizados para determinar a ocorrência dessa espécie no Brasil e a sua importância para a pecuária nacional.

Palavras-chave: Pediculose, *Haematopinus quadripertusus*, bovinos, piolhos, Phthiraptera, Pará, Brasil.

*Corresponding author: Alessandra Scofield

Laboratório de Parasitologia Animal, Programa de Pós-graduação em Saúde Animal na Amazônia, Faculdade de Medicina Veterinária, Universidade Federal do Pará – UFPA, Rua Hernani Lameira, 254B, Bairro Pirapora, CEP 68740-080, Castanhal, PA, Brasil
e-mail: ascofield@ufpa.br

Bovine pediculosis is a parasitic skin disease caused by different species of lice and has been reported in some countries around the world to lead to blood spoliation, anemia, severe pruritus, restlessness, stress, hair loss, decreased appetite, decreased weight gain and milk production, focal necrosis and scarring on the skin of heavily infested animals (PETERSON et al., 1953 apud SCHEMANKUK et al. 1960; GIBNEY et al., 1985). Sucking lice infestations can also lead to transmission of infectious agents like *Borrelia* spp. (BURGDORFER; HAYES, 1990) and favors the occurrence of keratoconjunctivitis and periorbital papillomatosis (YERUHAM et al., 2001).

The main species of lice that affect cattle are the chewing louse species *Bovicola bovis* and the sucking louse species *Linognathus vituli*, *Solenopotes capillatus*, *Haematopinus eurytenuis* and *Haematopinus quadripertusus* (NEW ZEALAND, 2008).

The family Haematopinidae includes the biggest louse parasites of domestic animals. This family contains a single genus, *Haematopinus*, and all its species are of veterinary importance. *H. eurytenuis* is reported mainly on cattle in temperate countries, while *H. quadripertusus* infests cattle in countries with tropical or subtropical climates. These ectoparasites fulfill their entire life cycle on a vertebrate host, surviving only a few hours outside the host's body (GUIMARÃES et al., 2001).

In Brazil, louse infestations on cattle are poorly reported. There are records only from the states of Minas Gerais, Sergipe (LINARDI; NEGROMONTE, 1987) and Rio Grande do Sul (ALVES-BRANCO et al., 2001). Because of the importance of these parasites that infest cattle and the economic losses brought about by them within Brazilian territory, it becomes necessary to study their occurrence and take measures to establish the control and prophylaxis.

The objective of this study was to identify the louse species found on cattle on a farm in the municipality of São Domingos do Capim, state of Pará.

On a farm property located on the PA-127 highway, in the municipality of São Domingos do Capim (01° 40' 27" S and 47° 46' 16" W), state of Pará, louse infestation was recognized on adult crossbred cows (*Bos taurus indicus* × *Bos taurus taurus*) that were being used as recipients in an embryo transfer program. Two visits were made to the farm, in November and December 2007, to visually inspect the entire herd of 65 animals and to collect the ectoparasites.

The louse specimens were collected manually and stored in test tubes containing 70% alcohol. They were then transported to the Animal Parasitology Laboratory, School of Veterinary Medicine, Federal University of Pará, where the specimens were observed under a stereoscopic microscope (Leica-EZ4D) for identification, determination sex, counting and measurement. Twenty specimens were also clarified in 10% KOH, dehydrated in an alcohol series and mounted between a slide and a cover slip, using Canada balsam diluted in xylene. These were observed under an optical microscope (Nikon E50I) to identify the species. The identification was made in accordance with the species key in Meleney and Kim (1974).

The adult lice were identified as *H. quadripertusus*, and all the animals examined (n = 65) presented at least one development stage of this ectoparasite (Figures 1 and 2). The specimens examined

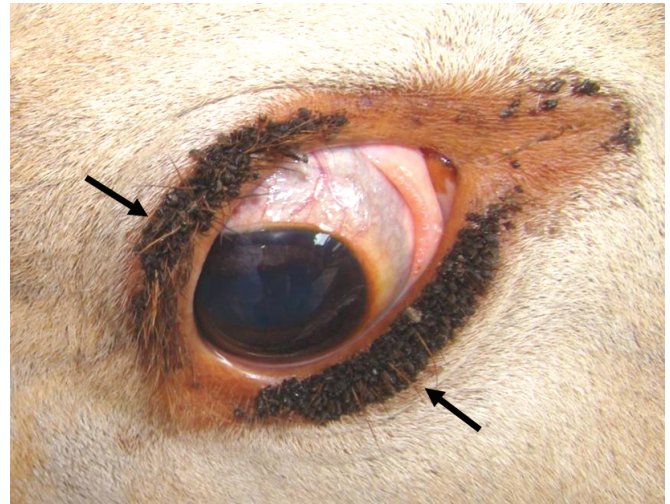


Figure 1. Infestation by *Haematopinus quadripertusus* on the bovine periocular region (black arrow).



Figure 2. *Haematopinus quadripertusus*: Nits (yellow arrow) and adults (white arrow) on the tail of a cow with intense infestation.

exhibited a sternal plate with long sharp anteromedian projections in both the male and female specimens, and the males exhibited a genital plate. The female specimens (n = 116) measured on average 4.14 ± 0.48 mm in length, while the males (n = 17) and nymphs (n = 92) measured on average 3.44 ± 0.39 mm and 2.45 ± 0.65 mm, respectively.

In relation to the distribution of lice on the bodies of the cattle examined, parasitism was only observed on the tail region in 80% (52/65) of the animals (Figure 2), while it was observed on the hair and skin of the periocular region, as well as on the ears and tail, in 20% (13/65) of the cattle examined (Figures 1 and 2). Regarding the developmental form of the parasite, nits, nymphs and adults were collected, respectively, on 98.46% (64/65), 38.46% (25/65) and 23.08% (15/65) of the animals examined.

For a long time, *H. eurytenuis* was considered to be the only species able to infect cattle. This species was subsequently reclassified and renamed by Meleney and Kim (1974) based on morphological features, locations of parasitism on the vertebrate host and geographical distribution.

Bovine pediculosis has been reported in several countries, but in Brazil, studies on the species of lice that infest cattle and the importance of the economic losses brought about by them are still only just beginning.

In Brazil, the report on this ectoparasitosis was made by Linardi and Negromonte (1987), who observed infestation by *H. quadripertusus* on cattle in the municipalities of Nuanque and Unaí, state of Minas Gerais and Aracaju, state of Sergipe. In Rio Grande do Sul, infestations by *L. vituli* on cattle were reported during the winter (ALVES-BRANCO et al., 2001). Here, we observed infestation by *H. quadripertusus* on 65 cattle, and this was the first report of bovine pediculosis in the state of Pará.

Infestations with more than one species of lice were reported in some countries. In Namibia, George et al. (1992) studied mite and louse infestations on different domestic animal species and found that cattle were infested with *L. vituli*, *S. capillatus* and *Haematopinus bovis*. Colwell et al. (2001) reported infestations by *L. vituli*, *S. capillatus*, *B. bovis* and *H. eurysternus* in Alberta of Canada, with occurrences of mixed infestation by *L. vituli* and *B. bovis*; infestations by the long-nosed sucking louse, *L. vituli*, were the most frequent occurrence. In England, Milnes et al. (2003) observed natural infestations by lice on 61 cattle during two consecutive winters, with a mixture of infestation by *B. bovis* and *S. capillatus*. In 1993, Gabaj et al. noticed infestation by *H. quadripertusus* and *L. vituli* on cattle in Libya and Pakistan. In other study, also in Pakistan, Kakar and Kakarsulemankhel (2009) cited louse prevalence of 38.3% (349/909) on cattle and 41.2% (277/671) on buffaloes. In that study, only *B. bovis* was found on cattle, whereas among buffaloes, 23.5% were infested by *H. quadripertusus* and 17.7% by *H. eurysternus*.

In Brazil, single infestation by *H. quadripertusus* was reported on cattle from Minas Gerais and Sergipe states (LINARDI; NEGROMONTE, 1987) and these findings resembled the results from the present study in Pará, where 100% of the animals examined also exhibited single infestation by *H. quadripertusus*.

Some animals can be particularly susceptible to infestation by lice, such as young cattle that are malnourished and stressed (YERUHAM et al., 2001). This was not observed in the present study, in which infestations by *H. quadripertusus* were reported in embryo-recipient cows that presented good body conditions.

Each louse species has its own preferred site on the hosts. *S. capillatus* mainly parasitizes the nose, mouth region, neck, back and tail, while *B. bovis* is found on the apex of the head, on the region of the mouthpiece, neck and back. The louse *L. vituli* is found more frequently on the mouth region, neck and posterior region of young dairy cattle, since *H. eurysternus* preferentially infests the head and neck of cattle raised in countries with cold climates, while *H. quadripertusus* is found mainly on the head, tail, long hair and vulvar and perineal regions of cattle raised in countries with tropical or subtropical climates (GUIMARÃES et al., 2001).

In this study, we observed louse infestation on the head region (eyelids and ears) and skin and hair of the tail of cattle, as also observed by Linardi and Negromonte (1987), who found infestation by *H. quadripertusus* on the ears, neck and tail hairs on cattle in the states of Minas Gerais and Sergipe. However, on the farm studied here, we observed that the majority of the females occurred on the tail, where they also put their nits. In

Israel, *H. quadripertusus* was observed on the shell, vulva and eyelids of heifers, while the nits were seen on the hair of the tail tip and auricular areas (YERUHAM et al., 2001).

It's important to highlight that all development forms of the parasite were observed during the two visits to the farm. The nits were more frequent than the other stages and this may have occurred due to the large oviposition capacity from *H. quadripertusus* and the short period of the adult's longevity (GUIMARÃES et al., 2001).

It was not possible to determine whether the *H. quadripertusus* infestation on cattle in São Domingos do Capim was autochthonous, since some of the animals had come from different Brazilian states. However, the environmental conditions have enabled maintenance of the ectoparasite population, since lice were observed on the cattle during two visits to the farm property. Because of the likely distribution of *H. quadripertusus* in Brazil, Linardi and Negromonte (1986) considered that this was the main species of lice on cattle in Brazil.

Conclusion

This is the first report of bovine pediculosis caused by *H. quadripertusus* in the state of Pará, and further studies should be conducted to determine the occurrence pattern of this species in Brazil and its importance to livestock.

References

- Alves-Branco FPJ, Pinheiro AC, Sapper MFM. *Vale a pena lembrar aos criadores de bovinos: O controle dos piolhos dos bovinos (Damalinia bovis e Linognathus vituli)*. Embrapa Pecuária Sul; 2001. 2 p. Comunicado Técnico, n. 41.
- Burgdorfer W, Hayes SF. Vector-spirochete relationships in louse-borne and tick-borne borrelioses with emphasis on Lyme disease. *Adv Dis Vector Res* 1990; 6: 127-150. http://dx.doi.org/10.1007/978-1-4612-3292-6_5
- Colwell DD, Clymer B, Booker CW, Guichon PT, Jim GK, Schunicht OC, et al. Prevalence of sucking and chewing lice on cattle entering feedlots in southern Alberta. *Can Vet J* 2001; 42(4): 281-285.
- Gabaj MM, Beesley WN, Awan MA. Lice of farm animals in Libya. *Med Vet Entomol* 1993; 7(2): 138-140. <http://dx.doi.org/10.1111/j.1365-2915.1993.tb00666.x>
- George JB, Ootobo S, Ogunleye J, Adedimiyi B. Louse and mite infestation in domestic animals in northern Nigeria. *Trop Anim Health Prod* 1992; 24(2): 121-124. <http://dx.doi.org/10.1007/BF02356957>
- Gibney VJ, Campbell JB, Boxler DJ, Clanton DC, Deutscher GH. Effects of various infestation levels of cattle lice (Mallophaga: Trichodectidae and Anoplura: Haematopinidae) on feed efficiency and weight gains of beef heifers. *J Econ Entomol* 1985; 78(6): 1304-1307.
- Guimarães JH, Tucci EC, Barros-Battesti DM. *Ectoparasitos de Importância Veterinária*. São Paulo: Plêiade; 2001; 213p.
- Kakar MN, Kakarsulemankhel JK. Prevalence of lice species on cows and buffaloes of Quetta, Pakistan. *Pakistan Vet J* 2009; 29(1): 49-50.
- Linardi PM, Negromonte MRS. Novos registros e dispersão de Haematopinídeos em bovinos no Brasil. *Arq Bras Med Vet Zootec* 1987; 39(6): 897-904.

- Meleney WP, Kim KC. A comparative study of cattle-infesting *Haematopinus*, with redescription of *H. quadripertusus* Farenholz, 1919 (Anoplura: Haematopinidae). *J Parasitol* 1974; 60(3): 507-522. <http://dx.doi.org/10.2307/3278373>
- Milnes AS, O'Callaghan CJ, Green LE. A longitudinal study of a natural lice infestation in growing cattle over two winter periods. *Vet Parasitol* 2003; 112(4): 307-323. [http://dx.doi.org/10.1016/S0304-4017\(02\)00390-4](http://dx.doi.org/10.1016/S0304-4017(02)00390-4)
- New Zealand. Ministry of Agriculture and Forestry. Lice. In: Draft Import Risk Analysis: Cattle from Australia, Canada, the European Union and the United States of America. 2008. p. 159-161. Draft for Public Consultation.
- Peterson HO, Roberts IH, Becklund WW, Kemper HE. Anemia in cattle caused by heavy infestations of the blood-sucking louse: *Haematopinus eurysternus*. *J Am Vet Med Assoc* 1953; 122(914): 373-376.
- Yeruham I, Hadani A, Perl S, Elad D. Keratoconjunctivitis and periorbital papillomatosis associated with heavy periorbital infestation by the tail louse *Haematopinus quadripertusus* in heifers. *J Vet Med B* 2001; 48(2): 133-136. <http://dx.doi.org/10.1046/j.1439-0450.2001.00425.x>
- Schemankuk JA, Haufe WO, Thompson COM. Anemia in range cattle heavily infested with the short-nosed sucking louse, *Haematopinus eurysternus* (Nitz) (Anoplura: Haematopinidae). *Can J Comp Med Vet Sci* 1960; 24(5): 158-161.