

Evaluation of Kato-Katz and spontaneous sedimentation methods for the diagnosis of platynosomiasis in Neotropical primates

Avaliação dos métodos de sedimentação espontânea e Kato-Katz para o diagnóstico da platinossomose em primatas neotropicais

Vitor Luís Tenório Mati^{1*}; Hudson Alves Pinto¹; Alan Lane de Melo¹

¹Departamento de Parasitologia, Instituto de Ciências Biológicas, Universidade Federal de Minas Gerais – UFMG, Belo Horizonte, MG, Brasil

Received October 10, 2014

Accepted November 5, 2014

Abstract

Platynosomiasis is a parasitic infection reported in non-human primates, including marmosets, and is frequently difficult to diagnose. In this study, the Kato-Katz method and the spontaneous sedimentation method were evaluated for their usefulness in identifying *Platynosomum* eggs in fecal samples from *Callithrix penicillata* that naturally harbor *Platynosomum illiciens*. Spontaneous sedimentation allowed the diagnosis of 41.7% (5/12) and 66.7% (8/12) of infected marmosets from one and three slides, respectively, prepared from the same fecal sample. The examination of a single Kato-Katz thick smear detected 83.3% (10/12) of infection cases. The analysis of feces on three different days increased the rate of diagnosis, since 75% (9/12) and 100% (12/12) of the primates with platynosomiasis were identified using serial spontaneous sedimentation (3 slides/day) and the Kato-Katz method, respectively. The mean number of *Platynosomum* eggs per gram of feces determined via the Kato-Katz method was 71.7 (8-240). The spontaneous sedimentation method when performed in series is acceptable for the diagnosis of platynosomiasis. However, the Kato-Katz method, which was here used for the first time to detect this infection, has a higher diagnostic sensitivity and the advantage that a quantitative analysis of the eggs released in the host feces is possible.

Keywords: Fecal parasitological diagnosis, platynosomiasis, *Platynosomum*, marmosets, spontaneous sedimentation, Kato-Katz thick smear.

Resumo

A platinossomose é uma infecção parasitária relatada em primatas não-humanos, inclusive saguis, cujo diagnóstico é frequentemente difícil. Neste estudo, os métodos de sedimentação espontânea e Kato-Katz foram avaliados quanto à sua utilidade na identificação de ovos de *Platynosomum* em amostras fecais de *Callithrix penicillata* naturalmente albergando *Platynosomum illiciens*. A sedimentação espontânea permitiu o diagnóstico de 41,7% (5/12) e 66,7% (8/12) dos saguis infectados a partir da análise de uma e três lâminas, respectivamente, preparadas de uma mesma amostra fecal. O exame de uma única lâmina de Kato-Katz detectou 83,3% (10/12) dos casos de infecção. A análise de fezes em três dias diferentes aumentou as taxas de diagnóstico, uma vez que 75% (9/12) e 100% (12/12) dos primatas que apresentaram a platinossomose foram identificados, usando-se a sedimentação espontânea (três lâminas/dia) e o Kato-Katz em série, respectivamente. O número médio de ovos de *Platynosomum* por g de fezes, determinado através do método de Kato-Katz, foi de 71,7 (8-240). O método de sedimentação espontânea, quando realizado em série, é aceitável para o diagnóstico da platinossomose. Entretanto, o método de Kato-Katz, o qual foi pela primeira vez usado para se detectar essa infecção, mostrou uma maior sensibilidade diagnóstica, com a vantagem de que é possível uma análise quantitativa dos ovos liberados nas fezes do hospedeiro.

Palavras-chave: Diagnóstico parasitológico fecal, platinossomose, *Platynosomum*, saguis, sedimentação espontânea, Kato-Katz.

*Corresponding author: Vitor Luís Tenório Mati, Laboratório de Taxonomia e Biologia de Invertebrados, Departamento de Parasitologia, Instituto de Ciências Biológicas, Universidade Federal de Minas Gerais – UFMG, CP 486, CEP 30123-970, Belo Horizonte, MG, Brasil, e-mail: vitormati@yahoo.com.br

Platynosomiasis, a parasitic disease caused by dicrocoeliid trematodes of the genus *Platynosomum*, often results in lesions in the biliary tract and gallbladder of birds and mammals harboring the adult parasite (RODRIGUES, 1963; KAZACOS et al., 1980; FOLEY, 1994; FERREIRA et al., 1999; ANDRADE et al., 2012; BASU & CHARLES, 2014). In South America, the terrestrial mollusk *Subulina octona* and some isopods (Oniscidea species and *Nagurus nanus*) are the first and second intermediate hosts, respectively, of the fluke. Lizards are also involved in this life cycle as paratenic hosts (PINTO et al., 2014).

Species of *Platynosomum* have been reported in nonhuman primates, including apes (*Pongo* sp.), Old World (*Macaca fascicularis*) and New World monkeys (*Callicebus moloch*, *Callimico goeldii*, *Callithrix* spp., *Cebuella pygmaea*, *Chiropotes satanas*, and *Saguinus* spp.) (KINGSTON & COSGROVE, 1967; COSGROVE et al., 1968; SHANTA, 1970; PORTER, 1972; TANTALEAN et al., 1990; WARREN et al., 1998; MELO, 2004; KAWHAGE et al., 2005; SOUSA et al., 2008; SILVA et al., 2012). Clinical manifestations have been absent or mild among New World monkeys infected with *Platynosomum*, although some deaths have also be attributed to the parasite (MELO, 2004; SOUSA et al., 2008; SILVA et al., 2012). The prognosis of the disease depends on the severity of chronic fibrosing hepatopathy, which is likely to be correlated with the parasite burden and the individual infected host response (SOUSA et al., 2008). Thus, a highly sensitive quantitative method of stool analysis is desirable for the diagnosis of platynosomiasis. Most new cases of the infection in nonhuman primates are diagnosed during necropsies, and coproparasitological diagnostic studies are rarely performed. As a result, primate specimens harboring *Platynosomum* spp. cannot usually be subjected to effective therapeutic intervention.

Considering that the veterinary management of primate platynosomiasis, including parasitological diagnosis, is still little known, the aim of the present study was to evaluate and compare the accuracy of two coproparasitological methods, the Kato-Katz method and spontaneous sedimentation, in identifying *Platynosomum* eggs in the feces of black-tufted marmosets (*Callithrix penicillata*), which are naturally infected with *P. illiciens*. In addition, previously published findings relating to other parasitological methods that have already been employed for the diagnosis of platynosomiasis in non-primate host are discussed.

Captive specimens of *C. penicillata* (n = 12; 7 females and 5 males) that were naturally infected with *Platynosomum illiciens*

(= *P. fastosum*) and maintained in the marmoset facility of the Instituto de Ciências Biológicas (ICB) of the Universidade Federal de Minas Gerais (UFMG) were studied. The definitive diagnosis of chronic infection with *P. illiciens* in each subject had been previously determined by a long series of routine parasitological tests using spontaneous sedimentation technique.

In this study, fresh samples of feces from all of these known positive marmosets were then collected three times in a week in order to evaluate the accuracy of the spontaneous sedimentation method (LUTZ, 1919) and the Kato-Katz method (KATZ et al., 1972).

One to three slides of fecal sediment obtained by spontaneous sedimentation were examined per day for each daily sample, but when the first slide examined was found to be positive for infection, no further analysis of the other slides was performed. This technique was chosen as the standard parasitological test because it is commonly used in Brazilian laboratories for the screening of helminth infections of wild animals.

Regarding the Kato-Katz thick smear, only one slide was prepared and examined per day. Once a positive result was obtained, no further testing was performed on subsequent days. In the quantitative analysis, the trematode eggs present in the Kato-Katz thick smears were counted and the number of eggs per gram of feces (g^{-1}) was estimated. Briefly, each fecal sample was placed on paper and sieved through a screen using a small metal spatula. Sieved feces were deposited into a well in a plastic template (41.7 mg of feces) on a microscope slide and then covered with cellophane coated in glycerol and malachite green. This preparation was pressed against a hard surface to spread the sample evenly on top of the slide (a thick smear preparation). The number of *Platynosomum* eggs observed in each thick smear was multiplied by 24 to estimate the number of eggs per gram of feces (KATZ et al., 1972). All slides were evaluated under a light microscope (100 \times total magnification) by the same author.

The sensitivity of each method was calculated and the McNemar test was used to compare data obtained, where differences were considered significant if $p < 0.05$. The use of marmosets was authorized by the Brazilian Institute of the Environment (Instituto Brasileiro do Meio Ambiente e Recursos Naturais Renováveis, IBAMA), and the experimental procedures were conducted in accordance with the animal research ethics committee of UFMG.

Both parasitological methods enabled the observation of typical eggs of *Platynosomum* in feces of *C. penicillata* (Figure 1).

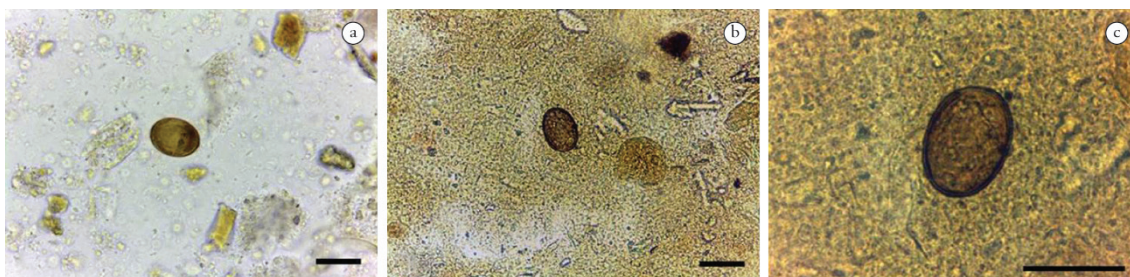


Figure 1. Eggs of *Platynosomum illiciens* observed during fecal analysis of specimens of naturally infected *Callithrix penicillata*, by using spontaneous sedimentation (a) and the Kato-Katz method (b). (c) Detail of a parasite egg in a Kato-Katz thick smear at a higher magnification. Scale bars = 40 μm .

a good parasitological method for the diagnosis of infection in domestic cats (FOLEY, 1994; BASU & CHARLES, 2014). A sensitivity of up to 100% (9/9 cats) has already been reported for this technique (PALUMBO et al., 1974), and it has been observed to have a greater capacity for detecting feline platynosomiasis in comparison to a direct smear, centrifugation in zinc sulfate, or modified detergent and sugar flotations (PALUMBO et al., 1976; KRECEK et al., 2010). Leal et al. (2011) achieved greater success in the identification of infected cats using serial formalin-ether sedimentation (80%; 8/10 cats) compared to a serial saturated sucrose flotation (only 3 cats), and confirmed previous observations that indicated that sedimentation methods are better than flotation methods for finding *Platynosomum* eggs. In general, this kind of test is considered superior to flotation techniques for observation of trematode eggs because of their high density. Indeed, many trematode eggs do not float or only float in solutions with a high specific gravity (BALLWEBER et al., 2014). However, positive results were observed for 12.5% of the fecal samples (5/40) from cats when a method involving the centrifugal flotation of feces in a sugar solution was used, whereas all samples were negative when the centrifugal sedimentation technique was used (ROCHA et al., 2014). Moreover, the parasitological diagnosis of platynosomiasis using centrifugation-sedimentation method was already shown to have a low sensitivity, especially for infections with reduced number of trematodes, since eggs were only observed in the feces of 34.7% (77/222) of cats that presented flukes at necropsy (RETNASABAPATHY & PRATHAP, 1971).

Different qualitative methods have already been evaluated for the diagnosis of platynosomiasis, but spontaneous sedimentation, to our knowledge, has been largely unnoticed, except for a report of it having a high sensitivity in cats (KRECEK et al., 2010). This relative lack of studies of spontaneous sedimentation may be because of the already widespread use of the formalin-ether technique in the diagnosis of feline platynosomiasis, at least considering the published cases. In the present study, the sensitivity of the spontaneous sedimentation technique was lower when only one slide was analyzed. However, the serial evaluation over three consecutive days increased the diagnostic sensitivity to a similar level to that observed for the Kato-Katz method. The easy preparation and low cost of the spontaneous sedimentation, besides the absence of contact with chemical products, may make it a good alternative tool for the diagnosis of platynosomiasis, especially when it is performed in series.

Successive analysis of slides to increase the sensitivity of the diagnostic method, including those prepared by formalin-ether sedimentation, has already been suggested (FOLEY, 1994; LEAL et al., 2011). This recommendation is more logical when one considers that, in cats, each specimen of *Platynosomum* produces between 10 and 100 eggs per day, which corresponds to only 2–10 g⁻¹ in the feces of a host infected with few (1–5) parasites. This information reinforces the finding that the number of eggs released in the feces varies not only according to the number of parasites, but also due to the intrinsically variable rate of egg deposition (PALUMBO et al., 1976).

Less attention has been given to quantitative fecal analysis in comparison to qualitative analysis of platynosomiasis. Among the different techniques evaluated so far for the parasitological

diagnosis of this infection, none is quantitative in the way that the Kato-Katz method is, although quantitative data have occasionally been presented (PALUMBO et al., 1976; TAYLOR & PERRI, 1977; LEAL et al., 2011). The use of this method to quantify the number of eggs may be comparatively easier than by quantitative formalin-ether sedimentation, which was adapted by Palumbo et al. (1976). In the present study, the Kato-Katz technique has shown a mean concentration of eggs in feces of 71.6 g⁻¹ among the marmosets infected with *P. illiciens*. This value resembles the quantitative data available for cats, but a comparison using this parameter alone may not be adequate due to biological differences between these definitive hosts. Perhaps with increased knowledge about the biology of the parasite in primate hosts it will be possible to estimate the parasite burden from the mean concentration of eggs in the feces obtained in serial fecal analyses.

In human parasitology, besides its demonstrated importance for the diagnosis of schistosomiasis (KATZ et al., 1972; WHO, 2013), the Kato-Katz method has also been used to diagnose fascioliasis (ESTEBAN et al., 1997; EL-MORSHEDEY et al., 2002), clonorchiasis (CHOI et al., 2005), opisthorchiasis (SOUKHATHAMMAVONG et al., 2011; LOVIS et al., 2012) and microcoeliasis (ASHRAFI, 2010; TAY et al., 2011). However, the Kato-Katz method is still not widely used in the diagnosis of animal trematodiasis. Anh et al. (2008) used three sensible diagnostic tests, including the Kato-Katz method, for the identification of small trematode eggs (<50 µm) in fecal samples of domestic animals. In addition to the Kato-Katz method, formalin-ether sedimentation and a more laborious method combining filtration, sedimentation, and centrifugation (the Danish Bilharziasis Laboratory [DBL] method) were evaluated. In their study, the sensitivity of the techniques of detection of small trematode eggs was the same in cats as in pigs, whereas the Kato-Katz method was slightly less sensitive in dogs. Anh et al. (2008) recognized that this last observation might be due to the amounts of feces evaluated being small and/or the lack of a washing procedure in the technique making the detection of eggs on the slide more difficult. Moreover, the influence of the different number of slides analyzed and the use of serial daily samples to increase the sensitivity of the diagnostic methods was not considered. Indeed, a limitation of the Kato-Katz technique is its low sensitivity for detecting eggs when they are present in small numbers in feces (theoretical analytic sensitivity of 1 egg/41.7 mg = 24 g⁻¹) (VLAS & GRYSEELS, 1992).

Considering the two parasitological methods evaluated in the present study, spontaneous sedimentation is easier to perform and cheaper than the Kato-Katz method, and when carried out in series is acceptable for the diagnosis of platynosomiasis in marmosets, and possibly in other hosts. The Kato-Katz method has a higher diagnostic sensitivity with the advantage that the number of eggs excreted in the feces of the infected host can be quantified. It is a practical method that may also be useful in veterinary practice for identification and monitoring *P. illiciens* infection and complementing existing diagnostic methods. Parasitological surveys in Neotropical primates should be encouraged in order to better understand the epidemiology of platynosomiasis in these hosts.

References

- Andrade RL, Dantas AF, Pimentel LA, Galiza GJ, Carvalho FK, Costa VM, et al. *Platynosomum fastosum*-induced cholangiocarcinomas in cats. *Vet Parasitol* 2012; 190(1-2): 277-280. <http://dx.doi.org/10.1016/j.vetpar.2012.04.015>. PMID:22963714
- Anh NTL, Phuong NT, Ha GH, Thu LT, Johansen MV, Murrell DK, et al. Evaluation of techniques for detection of small trematode eggs in faeces of domestic animals. *Vet Parasitol* 2008; 156(3-4): 346-349. <http://dx.doi.org/10.1016/j.vetpar.2008.05.021>. PMID:18583060
- Ashrafi K. Human microcoeliasis in northern Iran: two case reports from Gilan province. *Ann Trop Med Parasitol* 2010; 104(4): 351-353. <http://dx.doi.org/10.1179/136485910X12647085215813>. PMID:20659397
- Ballweber LR, Beugnet F, Marchiondo AA, Payne PA. American Association of Veterinary Parasitologists' review of veterinary fecal flotation methods and factors influencing their accuracy and use: is there really one best technique? *Vet Parasitol* 2014; 204(1-2): 73-80. <http://dx.doi.org/10.1016/j.vetpar.2014.05.009>. PMID:24893692
- Basu AK, Charles RA. A review of the cat liver fluke *Platynosomum fastosum* Kossack, 1910 (Trematoda: Dicrocoeliidae). *Vet Parasitol* 2014; 200(1-2): 1-7. <http://dx.doi.org/10.1016/j.vetpar.2013.12.016>. PMID:24412358
- Choi MH, Ge T, Yuan S, Hong ST. Correlation of egg counts of *Clonorchis sinensis* by three methods of fecal examination. *Korean J Parasitol* 2005; 43(3): 115-117. <http://dx.doi.org/10.3347/kjp.2005.43.3.115>. PMID:16192753
- Chung NY, Miyara AY, Chung G. The prevalence of feline liver flukes in the city and county of Honolulu. *J Am Anim Hosp Assoc* 1977; 13(2): 258-262.
- Cosgrove GE, Nelson B, Gengozian N. Helminth parasites of the tamarin, *Saguinus fuscicollis*. *Lab Anim Care* 1968; 18(6): 654-656. PMID:4235361.
- El-Morshedy H, Shehab AY, Zaki A, Farag HF. Intra-specimen and day-to-day variations of *Fasciola* egg counts in human stools. *East Mediterr Health J* 2002; 8(4-5): 619-625. PMID:15603045.
- Esteban JG, Flores A, Aguirre C, Strauss W, Angles R, Mas-Coma S. Presence of very high prevalence and intensity of infection with *Fasciola hepatica* among Aymara children from the Northern Bolivian Altiplano. *Acta Trop* 1997; 66(1): 1-14. [http://dx.doi.org/10.1016/S0001-706X\(97\)00669-4](http://dx.doi.org/10.1016/S0001-706X(97)00669-4). PMID:9177091
- Ferreira AM, Almeida EC, Labarthe NV. Liver fluke infection (*Platynosomum concinnum*) in Brazilian cats: prevalence and pathology. *Feline Pract* 1999; 27(2): 19-22.
- Foley RH. *Platynosomum concinnum* infection in cats. *Compend Contin Educ Pract Vet* 1994; 16(10): 1271-1277.
- Katz N, Chaves A, Pellegrino J. A simple device for quantitative stool thick-smear technique in Schistosomiasis mansoni. *Rev Inst Med Trop Sao Paulo* 1972; 14(6): 397-400. PMID:4675644.
- Kawhage P, Pereira WLA, Silva KSM, Carvalho RA. Helminthofauna de caráter zoonótico em primatas não humanos mantidos em cativeiro no Centro Nacional de Primatas (Ananindeua, Pará, Brasil). *Rev Univ Rural* 2005; 25(S1): 43-44.
- Kazacos KR, Dhillon AS, Winterfield RW, Thacker HL. Fatal hepatic trematodiasis in cockatoos due to *Platynosomum proxillicens*. *Avian Dis* 1980; 24(3): 788-793. <http://dx.doi.org/10.2307/1589818>. PMID:7447844
- Kingston N, Cosgrove GE. Two new species of *Platynosomum* (Trematoda: Dicrocoeliidae) from South American monkeys. *Proc Helminthol Soc Wash* 1967; 34(2): 147-151.
- Kreck RC, Moura L, Lucas H, Kelly P. Parasites of stray cats (*Felis domesticus* L., 1758) on St. Kitts, West Indies. *Vet Parasitol* 2010; 172(1-2): 147-149. <http://dx.doi.org/10.1016/j.vetpar.2010.04.033>. PMID:20537465
- Leal PDS, Campos DP, Rodrigues MLA, Botelho GG, Labarthe NV. Avaliação da administração oral de ácido ursodesoxicólico (AUDC) no diagnóstico da infecção natural por *Platynosomum illiciens* em gatos. *Rev Bras Med Vet* 2011; 33(4): 229-233.
- Lovis L, Mak TK, Phongluxa K, Aye Soukhathammavong P, Vonghachack Y, Keiser J, et al. Efficacy of praziquantel against *Schistosoma mekongi* and *Opisthorchis viverrini*: a randomized, single-blinded dose-comparison trial. *PLoS Negl Trop Dis* 2012; 6(7): e1726.
- Lutz A. O *Schistosomum mansoni* e a schistosomose, segundo observações feitas no Brasil. *Mem Inst Oswaldo Cruz* 1919; 11(1): 121-155. <http://dx.doi.org/10.1590/S0074-02761919000100006>.
- Melo AL. Helminths parasites of *Callithrix geoffroyi*. *Lab Prim Newsl* 2004; 43(2): 7-9.
- Palumbo NE, Perri SFO, Loo B, Taylor D, Reece V. Cat liver fluke, *Platynosomum concinnum*, in Hawaii. *Am J Vet Res* 1974; 35(11): 1455. PMID:4429247.
- Palumbo NE, Taylor D, Perri SF. Evaluation of fecal technics for the diagnosis of cat liver fluke infection. *Lab Anim Sci* 1976; 26(3): 490-493. PMID:940311.
- Pinto HA, Mati VLT, Melo AL. New insights into the life cycle of *Platynosomum* (Trematoda: Dicrocoeliidae). *Parasitol Res* 2014; 113(7): 2701-2707. <http://dx.doi.org/10.1007/s00436-014-3926-5>. PMID:24802870
- Porter JA Jr. Parasites of marmosets. *Lab Anim Sci* 1972; 22(4): 503-506. PMID:4340289.
- Ragozo AMA, Muradian V, Silva JCO, Caravieri R, Amajoner VR, Magnabosco C, et al. Ocorrência de parasitos gastrintestinais em fezes de gatos das cidades de São Paulo e Guarulhos. *Braz J Vet Res Anim Sci* 2002; 39(5): 244-246. <http://dx.doi.org/10.1590/S1413-95962002000500005>.
- Retnasabapathy A, Prathap K. The liver-fluke *Platynosomum fastosum* in domestic cats. *Vet Rec* 1971; 88(3): 62-65. <http://dx.doi.org/10.1136/vr.88.3.62>. PMID:5100594
- Ritchie LS. An ether sedimentation technique for routine stool examinations. *Bull US Army Med Dep* 1948; 8(4): 326. PMID:18911509.
- Rocha NO, Portela RW, Camargo SS, Souza WR, Carvalho GC, Bahiense TC. Comparison of two coproparasitological techniques for the detection of *Platynosomum* sp. infection in cats. *Vet Parasitol* 2014; 204(3-4): 392-395. <http://dx.doi.org/10.1016/j.vetpar.2014.04.022>. PMID:24877787
- Rodrigues HO. Contribuição ao estudo do gênero *Platynosomum* Looss, 1907: (Trematoda, Dicrocoeliidae). *Mem Inst Oswaldo Cruz* 1963; 61(3): 507-515. PMID:14141131.
- Shanta CS. A species of *Platynosomum* from a monkey. *Malaysian Vet J* 1970; 5(1): 17-18.
- Silva KS, Silva RJ, Pereira WL. Occurrence of infection by *Platynosomum illiciens* (Braun, 1901) in captive neotropical primates. *Primates* 2012; 53(1): 79-82. <http://dx.doi.org/10.1007/s10329-011-0281-3>. PMID:22071558
- Soukhathammavong P, Odermatt P, Sayasone S, Vonghachack Y, Vounatsou P, Hatz C, et al. Efficacy and safety of mefloquine, artesunate, mefloquine-artesunate, tribendimidine, and praziquantel in patients with *Opisthorchis viverrini*: a randomised, exploratory, open-label, phase 2 trial. *Lancet Infect Dis* 2011; 11(2): 110-118. [http://dx.doi.org/10.1016/S1473-3099\(10\)70250-4](http://dx.doi.org/10.1016/S1473-3099(10)70250-4). PMID:21111681

- Sousa MB, Leão AC, Coutinho JF, de Oliveira Ramos AM. Histopathology findings in common marmosets (*Callithrix jacchus* Linnaeus, 1758) with chronic weight loss associated with bile tract obstruction by infestation with *Platynosomum* (Loos, 1907). *Primates* 2008; 49(4): 283-287. <http://dx.doi.org/10.1007/s10329-008-0105-2>. PMID:18841441
- Souza-Dantas LM, Bastos OPM, Brener B, Salomão M, Guerrero J, Labarthe NV. Técnica de centrifugo-flutuação com sulfato de zinco no diagnóstico de helmintos gastrintestinais de gatos domésticos. *Ciênc Rural* 2007; 37(3): 904-906. <http://dx.doi.org/10.1590/S0103-84782007000300051>.
- Tantalean M, Gonzalo A, Montoya E. Notes on some helminth parasites from Peruvian monkeys. *Lab Prim Newsl* 1990; 29(2): 6-8.
- Tay SCK, Gbedema SY, Gyampomah TK. Accuracy of diagnosis of intestinal helminth parasites in a reference diagnostic laboratory in the Ashanti region of Ghana. *Int J Parasitol Res* 2011; 3(1): 12-16. <http://dx.doi.org/10.9735/0975-3702.3.1.12-16>.
- Taylor D, Perri SF. Experimental infection of cats with the liver fluke *Platynosomum concinnum*. *Am J Vet Res* 1977; 38(1): 51-54. PMID:402094.
- Vlas SJ, Gryseels B. Underestimation of *Schistosoma mansoni* prevalences. *Parasitol Today* 1992; 8(8): 274-277. [http://dx.doi.org/10.1016/0169-4758\(92\)90144-Q](http://dx.doi.org/10.1016/0169-4758(92)90144-Q). PMID:15463638
- Warren KS, Swan RA, Hobbs RP, Heriyanto, Kuhn EM, Heeney JL. *Platynosomum fastosum* in ex-captive orangutans from Indonesia. *J Wildl Dis* 1998; 34(3): 644-646. <http://dx.doi.org/10.7589/0090-3558-34.3.644>. PMID:9706579
- World Health Organization - WHO. *Assessing the efficacy of anthelmintic drugs against schistosomiasis and soil-transmitted helminthiases*. Geneva: WHO Press; 2013.