

Pathology and morphometry of *Hystrichis acanthocephalicus* (Nematoda) from *Phimosus infuscatus* (Pelecaniformes) in southern Brazil

Patologia e morfometria de *Hystrichis acanthocephalicus* (Nematoda) em *Phimosus infuscatus* (Pelecaniformes) no Sul do Brasil

Simone Scheer^{1*}; Márcia Raquel Pegoraro Macedo¹; Mauro Pereira Soares²; Camila Costa Schramm¹; Gertrud Muller¹

¹ Laboratório de Parasitologia de Animais Silvestres – LAPASIL, Departamento de Microbiologia e Parasitologia, Instituto de Biologia, Universidade Federal de Pelotas – UFPel, Campus Universitário Capão do Leão, Pelotas, RS, Brasil

² Departamento de Patologia Animal e Veterinária Preventiva, Universidade Federal de Pelotas – UFPel, Campus Universitário Capão do Leão, Pelotas, RS, Brasil

Received September 22, 2016

Accepted October 31, 2016

Abstract

Species of *Hystrichis* are parasite nematodes of the digestive tract of aquatic birds in South America, Europe and Asia. In Brazil, *Hystrichis acanthocephalicus* has been reported in *Phimosus infuscatus*. There are few data on the morphometry of this species and there are no reports on pathological conditions that it causes. Therefore, the purpose of this study was to report morphometric data from *H. acanthocephalicus* and describe the pathological effects of this parasite on the *Phimosus infuscatus* proventriculus. Thirty gastrointestinal tracts of *P. infuscatus* were examined to search for nematodes and *H. acanthocephalicus* occurred in 83% of hosts. Were measured the total length and body width of males and females, and of their respective cuticular spines, esophagus, spicules and eggs, and the internal and external diameter of copulatory bursa. Histopathological examination revealed parasitic structures in the proventriculus from the lumen (anterior end) to the outer layers of the organ (intermediate and posterior parts), in which we observed inflammatory reaction with infiltration of heterophils, hemorrhage and hemosiderin. The results of this study of histopathology, morphometry and parasitological indices are the first ones reported to *H. acanthocephalicus* and should contribute to the identification and recognition in cases of outbreaks in the Neotropical region.

Keywords: Aquatic bird, helminths, pathology, morphometry.

Resumo

Espécie de *Hystrichis* são nematoides parasitos do trato digestório de aves aquáticas, na América do Sul, Europa e Ásia. No Brasil, foi registrado *Hystrichis acanthocephalicus*, em *Phimosus infuscatus*. Existem poucos dados sobre a morfometria e não há registros relativos à patologia desta espécie. Portanto, o objetivo deste estudo foi relatar dados morfométricos de *H. acanthocephalicus* e descrever os efeitos patológicos deste parasito no proventrículo de *Phimosus infuscatus*. Foram examinados trinta tratos gastrintestinais de *P. infuscatus* para a pesquisa de nematoides e *H. acanthocephalicus* ocorreu em 83% dos hospedeiros. Mediu-se o comprimento total e largura do corpo de machos e fêmeas, dos espinhos cuticulares, do esôfago, dos espículos, dos ovos, respectivamente, e a largura interna e externa da bolsa copuladora. Nos exames histopatológicos foram encontradas estruturas parasitárias no proventrículo, desde o lúmen (porção anterior) até as camadas mais externas do órgão (porções intermediária e posterior), nas quais se observou reação inflamatória com infiltrado de heterófilos, presença de hemorragia e deposição de hemossiderina. Os resultados desse estudo sobre histopatologia, morfometria e índices parasitológicos são os primeiros relatados para *H. acanthocephalicus* e deverão contribuir para a identificação e reconhecimento em casos de surtos na região Neotropical.

Palavras-chave: Ave aquática, helmintos, patologia, morfometria.

*Corresponding author: Simone Scheer. Departamento de Microbiologia e Parasitologia, Instituto de Biologia, Universidade Federal de Pelotas – UFPel, Campus Universitário Capão do Leão, CP 354, CEP 96010-900, Pelotas, RS, Brasil. e-mail: sissi_sls@hotmail.com

Introduction

Diectophymatidae are composed of nematode species belonging to three genera that parasitize vertebrates: *Eustrongylides* Jägerskiöld, 1909 and *Hystrichis* Molin, 1861, which are parasites of the esophagus, proventriculus and/or gizzard of aquatic birds; and *Diectophyma* Goeze, 1782, which are parasites of the kidneys of wild and domestic carnivores. All the species include oligochaetes as intermediate hosts (ANDERSON, 2000).

Hendricks et al. (1969) established five species of *Hystrichis*: *Hystrichis coronatus* Molin, 1861 in the gizzard of *Mergus merganser* Linnaeus, 1758 (Anseriformes: Anatidae); *Hystrichis pachicephalus* Molin, 1861 in the gizzard of *Cygnus olor* Gmelin, 1789 (Anseriformes: Anatidae); *Hystrichis corvi* Hendricks, 1969, in the proventricular glands of *Corvus brachyrhynchos* Brehm, 1822 (Passeriformes: Corvidae); *Hystrichis tricolor* Dujardin, 1845 in the esophagus of *Anas tadorna* Linnaeus, 1758 (Anseriformes: Anatidae); and *Hystrichis acanthocephalicus* Molin, 1861 in the proventricular glands of *Phimosus infuscatus* Lichtenstein, 1823 (Pelecaniformes: Threskiornithidae), host that is object of this study.

Phimosus infuscatus known as the bare-faced ibis, inhabits shallow-water regions - flooded fields, wetlands and rice fields - where it finds the main items of its diet: aquatic arthropods, crustaceans, mollusks, seeds and leaves (BELTON, 2003). These birds are widely distributed throughout South America and can be observed in all seasons of the year (SICK, 1997).

The helminths reported in *P. infuscatus* in the Neotropical region include the cestode *Chimaerula bonai* Georgiev, 2000 (GEORGIEV & VAUCHER, 2000), the nematodes *Eustrongylides* sp. and *H. acanthocephalicus* and the trematode *Stomylotrema* sp. (TRAVASSOS & FREITAS, 1942). The objective of the present study was to describe the histopathological alterations to the proventriculus of *Phimosus infuscatus* caused by *Hystrichis acanthocephalicus* and to report new morphometric data on this parasite.

Materials and Methods

The birds examined were collected in the municipalities of Pelotas (31° 46' 19" S; 52° 20' 33" W), Capão do Leão (31° 46' 3" S; 52° 26' 55" W) and Rio Grande (31° 51' 12.1" S; 52° 18' 48.0" W), in Rio Grande do Sul State, Brazil. We examined thirty specimens of *P. infuscatus* (16 males and 14 females), nine of which were donated by the Núcleo de Reabilitação da Fauna Silvestre e Centro de Triagem de Animais Silvestres da Universidade Federal de Pelotas (NURFS-CETAS/UFPel), where they had died. The others were shot using hunting guns between December 2015 and February 2016, with authorization from the Instituto Chico Mendes de Conservação da Biodiversidade – Sistema de Autorização e Informação em Biodiversidade/ICMBIO-SISBIO no. 507541; and from the CEEA/UFPel ethics committee for animal use, under no. 21300013.

The necropsies on the birds and helminth collection and preparation followed the recommendations of Amato & Amato (2010).

The proventriculus of each bird was subjected to enzymatic digestion in order to collect parasites. This was done in a solution of 1% hydrochloric acid and 10% pepsin at 37 °C for 45 minutes. After collection of parasites, the specimens were fixed in AFA (solution of ethanol, formaldehyde and acetic acid) and stored in alcohol 70%. The nematodes were clarified using Amman's lactophenol and were observed under an Olympus CX21 microscope in order to identify them and obtain morphometric data. They were then identified morphologically (HENDRICKS et al., 1969). The ecological terms following the recommendations of Bush et al. (1997). Voucher specimens (male and female) were deposited in the Coleção de Helmintos do Laboratório de Parasitologia de Animais Silvestres do Instituto de Biologia, Universidade Federal de Pelotas (CHLAPASIL/UFPel), under the number 636.

For histopathological analysis, two proventriculus were fixed in 10% buffered formalin. Each proventriculus was processed in accordance with the recommendations of Caputo et al. (2009).

Results

Hystrichis acanthocephalicus was found in the proventriculus of 25 birds. A total of 90 specimens (58 females and 32 males) of *H. acanthocephalicus* was collected, with prevalence of 83%, average abundance of 3.0 and mean intensity of infection of 3.6 nematodes per host.

The morphometric description was based on five male specimens and five female specimens (adults) and 25 eggs. The females were slightly longer than the males (Table 1), with mean lengths of 37.9 mm and 32.5 mm, respectively. The spines are of uniform size at different points in the anterior end (Figure 1a). The eggs presented morphology specific to the species (Figure 1d and Figure 1e), with a symmetrical format covered by a thick, rough shell marked by a irregularly shaped ridges; morphologically characteristic of Diectophymatidae. A single spicule was seen in each male. The copulatory bursa also showed uniform measurements among the different specimens (Figure 1b).

In the histological analysis, we observed parasite structures in the proventriculus of *P. infuscatus*. Parasites were found with the anterior end inserted in the mucous glands, directed towards the lumen of the proventriculus. The intermediate and posterior regions were spread along the submucosa, muscle and adventitia layers (Figure 2a). The regions of parasite structures showed infiltration of heterophils, hemorrhage and hemosiderin (Figure 2b). The intermediate and posterior regions were mainly in the muscle and adventitia layers. In these regions, adult females with a pregnant uterus (Figure 2f) and calcified parasites (Figure 2c and Figure 2d) were found. The parasites were delimited by a conspicuous hypereosinophilic halo (cellular remains), a thick layer of multinucleated giant cells and a fibrous connective tissue capsule (Figure 2e). In addition, bordering these regions, a conspicuous inflammatory response with the presence of mononuclear cells and heterophils and hemosiderin (Figure 2b and Figure 2d) was observed. Some areas had necrotic crypts with cellular remains in the lumen and inflammatory responses of different degrees of severity (Figure 2g).

Table 1. Measurements on adults and eggs of *Hystrichis acanthocephalicus* collected from of *Phimosus infuscatus* (n = 30), from Rio Grande, Pelotas and Capão do Leão municipalities, in Rio Grande do Sul State. All measurements are in micrometers, except for the length and width of the body, which are in millimeters.

Feature	Females (n = 5)			Males (n = 5)		
		\bar{x}	SD		\bar{x}	SD
Body						
Overall length	32.9-42.9	37.9	±3.958	25.9-33.4	32.5	±3.44
Maximum width	1.5-1.8	1.646	±0.134	1.5-1.8	1.720	±0.117
Esophagus						
Overall length	7.3-7.85	7.516	±0.204	5.07-6.75	6.250	±0.673
Maximum width	0.22-0.28	0.258	±0.029	0.18-0.25	0.212	±0.029
Spicules						
Length				3.18-3.40	3.3	±0.09
Width				0.04-0.05	0.048	±0.004
Copulatory bursa						
Complete diameter				0.233-0.278	0.253	±0.016
Internal diameter				0.105-0.173	0.136	±0.024
Spines (n = 50)						
Length	0.023-0.035	0.029	±0.003	0.02-0.033	0.027	±0.004
Width	0.01-0.033	0.012	±0.004	0.01-0.03	0.013	±0.004
Eggs (n = 25)						
Length	0.07-0.09	0.078	± 0.006			
Width	0.04-0.06	0.0432	± 0.005			

SD = Standard deviation.

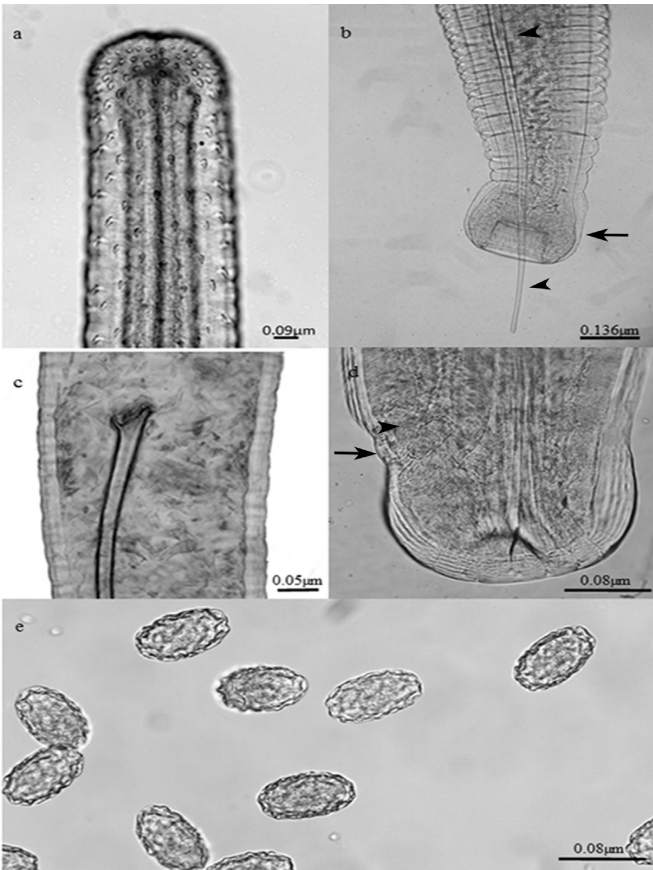


Figure 1. (a) Anterior end; (b) Posterior end of male showing the copulatory bursa (arrow) and the spicule (arrow tip); (c) Proximal end of spicule; (d) Posterior end of female showing the egg (arrow tip) in the vulvar opening (arrow); (e) Eggs.

Discussion

In Brazil, there is only one record of *H. acanthocephalicus* in the proventricular glands of *P. infuscatus* (VICENTE et al., 1995), but neither the number of birds examined nor the geographical location were reported. In the present study, the hosts were caught systematically and central geographical coordinates relative to the sampling points were supplied, including for the hosts that were donated by NURFS.

In the morphological description of *H. acanthocephalicus* in *P. infuscatus*, only the length and width measurements of the males and females were reported: 2 mm and 35 mm, and 35 mm and 3 mm (MOLIN, 1861), respectively. In the present study, we found differences in length and width, both among the males and among the females, thus agreeing with what was described by Molin (1861). The males were shorter and wider than the females (32.5 mm in length and 1.720 mm in width). The females, in turn, were slightly longer and narrower (37.9 mm in length and 1.646 mm in width) than those originally described, and in relation to the males. The esophagus and cuticular spicules of *P. infuscatus* were reported here for the first time. Hence, it was only possible to make morphometric comparisons with other species of *Hystrichis*.

Hystrichis acanthocephalicus is smaller than *H. corvi*: the females measure 90.70 mm x 2.11 mm and the males, 40.79 mm x 0.98 mm. However, the copulatory bursa of *H. corvi* is smaller, with a diameter of 138 µm (HENDRICKS et al., 1969), compared with 253 µm for *H. acanthocephalicus* (Figure 1b and Figure 1c). Reports of the female length and width are available for *H. tricolor* and

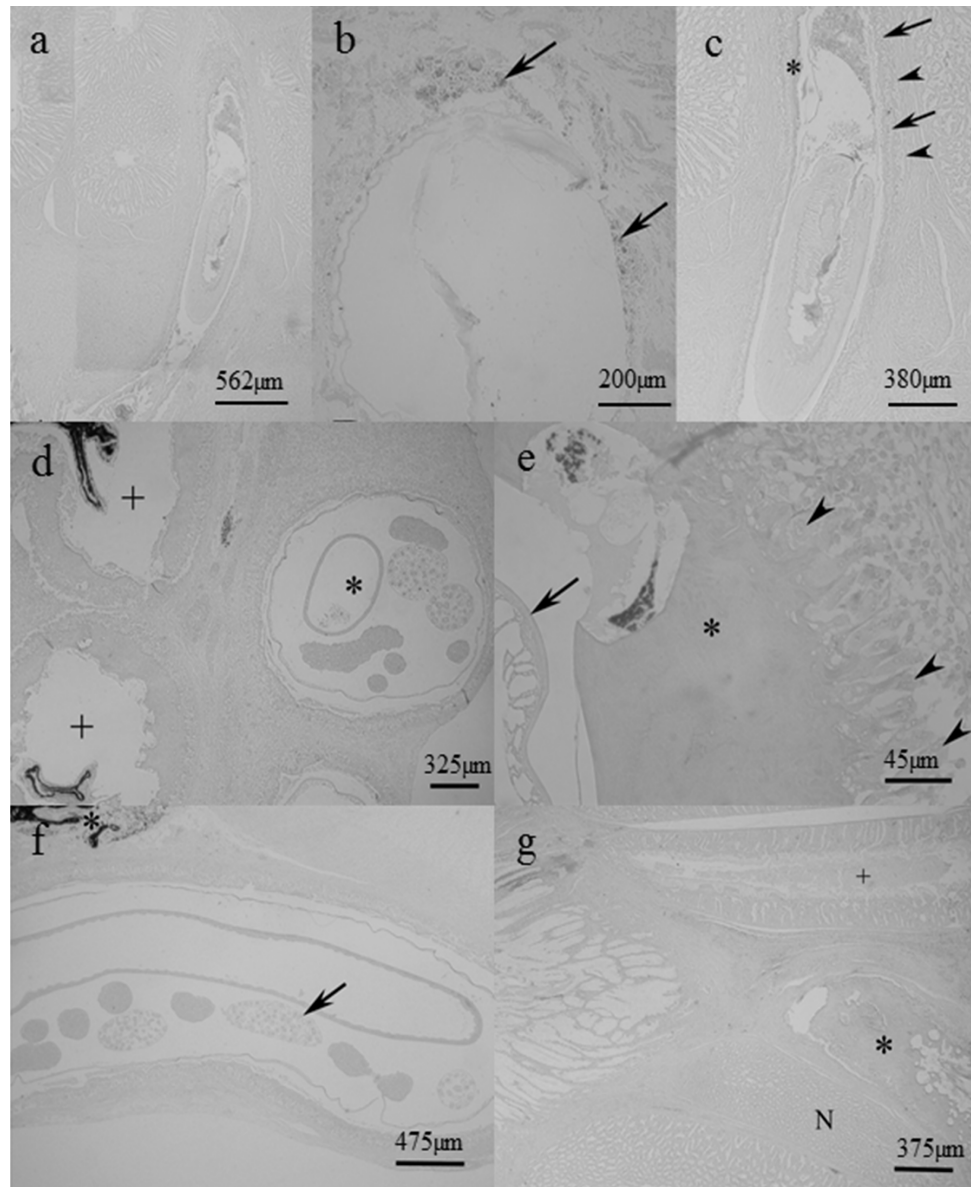


Figure 2. (a) Parasite encapsulated in the proventriculus, extending from the mucosa to the adventitia; (b) Hemosiderin around the anterior end (arrow); (c) Parasite bounded by necrosis (*), inflammatory multinucleated cells (arrow) and fibrosis (arrow tip); (d) Viable parasite (*) bounded by hypereosinophilic halo, surrounded by infiltrated inflammatory of multinucleated giant cells, fibrosis and abundant inflammatory infiltrate of mononucleosis; necrotic parasite (+); (e) External cuticle of the parasite (arrow); necrotic tissue surrounding the parasite (*) and multinucleated giant-cell layer (arrow tip); (f) Adult parasite in adventitia layer; gravid uterus with eggs (arrow); remains of parasite undergoing degradation process and necrosis (*); (g) Normal crypt (N); parasite inside crypt (*); crypt undergoing degeneration process with remains of cells in the lumen (+).

H. coronatus: 35 mm x 5 mm, and 27 mm x 3 mm, respectively. For *H. pachicephalus*, only the length of the female is known: 30 mm (MOLIN, 1861). Thus, there is a small difference in relation to the measurements of *H. acanthocephalicus*.

Hystrichis acanthocephalicus and *H. tricolor* can be differentiated through the morphology of the eggs (HENDRICKS et al., 1969). *Hystrichis acanthocephalicus* has a shell marked by a network of irregularly shaped ridges and the eggs measure 0.078 µm in length x 0.0432 µm in width. *Hystrichis tricolor* has eggs of regular shape, measuring 85 µm by 50 µm (AL-LABBAN et al., 2013). The irregular shape of *H. acanthocephalicus* eggs, along with the disposition

of cuticular spines, was essential for species identification in the present study. The morphometric data generated were important for species differentiation.

Hystrichis spp. have been reported in many hosts and geographical regions with varied prevalence, mean abundance and intensity: *Hystrichis tricolor* was reported in *Anas platyrhynchos*, in Poland (KAVETSKA et al., 2012) with P = 0.19%; and larvae of *H. tricolor* were reported in *Bufo viridis*, in Uzbekistan (VASHETKO & SIDDIKOV, 1999), with A = 0.004 and MI = 0.4, and *B. viridis* is probably a paratenic host. Al-Labban et al. (2013) reported *H. tricolor* with P = 10%, in ducks (Anatidae), in Iraq.

Youssefi et al. (2010) provided the first report of *Hystrichis* sp. in the digestive tract of otters (*Lutra lutra*), in Iran. In a comparative study between *Gallinula chloropus cachinnans* and *Porphyryla martinica* (Rallidae), in Florida, Kinsella et al. (1973) found *H. tricolor* with prevalence of 10% for *Gallinula chloropus cachinnans* and 2% for *Porphyryla martinica* (Rallidae), in the proventriculus of both birds. Canaris et al. (2010), in Mexico, reported *H. tricolor* with P = 58% and A = 5.08 in *Limnodromus scolopaceus* (Scolopacidae). The results from these studies, except Canaris et al. (2010), show distinctly lower rates than those in *P. infuscatus* (P = 83%). We attribute this difference in prevalence to the climatic conditions of the places where the studies were conducted. The higher prevalence in Mexico and Brazil, which are both in the Neotropical region, probably occurred because of better environmental conditions for the intermediate hosts throughout the year. In the Palearctic and Nearctic regions, the intermediate hosts can complete the life cycle in the summer.

The pathological effects of *H. acanthocephalicus* have not yet been described. However, the histopathological changes caused by *H. tricolor* in the proventriculus of ducks were reported by Al-Labban et al. (2013), who observed that the cells were distributed irregularly, with infiltration of inflammatory cells. In addition to the inflammatory response in *P. infuscatus* of this study, parasites were found encapsulated and calcified. Similar inflammatory reactions were also reported by Clark (1978) in relation to *Tetrameres tarapungae* Clark 1978, in which the anterior end is also characterized by spines and the organ selected is the proventriculus.

Histrichosis is rare, but can cause large impacts on bird populations, as has been reported in Russia, Ukraine, and Georgia (KARMANOVA, 1986). Our new information on the histopathology of *H. acanthocephalicus*, in association with morphometric and prevalence data, among other information, will make it possible to recognize outbreaks in the Neotropical region. Finally, the parasitological indices of *H. acanthocephalicus* in *P. infuscatus* reported here were the first records for the Neotropical region.

Acknowledgements

We thank the Núcleo de Reabilitação da Fauna Silvestre/ Universidade Federal de Pelotas and the Instituto Chico Mendes de Conservação da Biodiversidade – Sistema de Autorização e Informação em Biodiversidade, for the license to catch the birds.

References

Al-Labban NQM, Dawood KA, Jassem GA. New parasites of local duck recorded in Iraq with histopathological study. *Al-Qadisiya J Vet Med Sci* 2013; 12(1): 152-161.

Amato JFR, Amato SB. Técnicas gerais para coleta e preparação de helmintos endoparasitos de aves. In: Von Matter S, Straube FC, Piacentini VQ, Accordi IA, Cândido JF Jr. *Ornitologia e conservação: ciência aplicada, técnicas de pesquisa e levantamento*. Rio de Janeiro: Technical Books; 2010. p. 367-394.

Anderson RC. *Nematode parasites of vertebrates: their development and transmission*. London: CABI International; 2000.

Belton W. *Aves do Rio Grande do Sul: distribuição e biologia*. São Leopoldo: Editora UNISINOS; 2003.

Bush AO, Lafferty KD, Lotz JM, Shostak AW. Parasitology meets ecology on its own terms: Margolis et al. revisited. *J Parasitol* 1997; 83(4): 575-583. PMID:9267395. <http://dx.doi.org/10.2307/3284227>.

Canaris AG, Ortiz R, Canaris GJ. A predictable suite of helminth parasites in the long-billed dowitcher, *Limnodromus scolopaceus*, from the Chihuahua Desert in Texas and Mexico. *J Parasitol* 2010; 96(6): 1060-1065. PMID:21158610. <http://dx.doi.org/10.1645/GE-2503.1>.

Caputo LFG, Giritana LB, Manso PPA. Técnicas histológicas. In: Molinaro EM, Caputo LFG, Amendoeira MRR. *Conceitos e métodos para a formação de profissionais em laboratórios de saúde*. 2nd ed. Rio de Janeiro: Clark W; 2009. p. 89-188.

Clark WC. *Tetrameres tarapungae* n. sp. (Nematoda: Spirurida), a parasite of the red billed gull, *Larus novaehollandiae scopulinus*. *NZ J Zool* 1978; 5(1): 7-13. <http://dx.doi.org/10.1080/03014223.1978.10423742>.

Georgiev BB, Vaucher C. *Chimaerula bonai* sp. n. (Cestoda: Dilepididae) from the bare-faced ibis, *Phimosus infuscatus* (Lichtenstein) (Aves: Threskiornithidae) in Paraguay. *Folia Parasitol (Praha)* 2000; 47(4): 303-308. PMID:11151955. <http://dx.doi.org/10.14411/fp.2000.052>.

Hendricks LD, Harkema R, Miller GC. *Hystrichis corvi* sp. n. (Nematoda: Dioctophymatidae) from the Crow, and a Revised Key to the Species of *Hystrichis*. *J Parasitol* 1969; 55(6): 1201-1204. <http://dx.doi.org/10.2307/3277258>.

Karmanova EM. *Dioctophymidea of animals and man and diseases caused by them: fundamentals of nematology*. Washington: U.S. Department of Agriculture and the National Science Foundation; 1986.

Kavetska KM, Pilarczyk B, Królaczyk K. Stomach nematodes of wild ducks (Subfamily Anatinae) wintering in the North-Western Poland. *Bull Vet* 2012; 56(1): 27-31.

Kinsella JM, Hon L, Reed PB Jr. A comparison of the helminth parasites of the common gallinule (*Gallinula chloropus cachinnans*) and the purple gallinule (*Porphyryla martinica*) in Florida. *Am Midl Nat* 1973; 89(2): 467-473. <http://dx.doi.org/10.2307/2424053>.

Molin R. *Il sottordine degli acrofalli ordinato scientificamente secondo i risultati delle indagini anatomiche ed embriogeniche*. Venezia: Presso la Segreteria dell'IR Institutó; 1861.

Sick H. *Ornitologia Brasileira*. Rio de Janeiro: Editora Nova Fronteira; 1997.

Travassos L, Freitas JFT. Relatório da sexta excursão do Instituto Oswaldo Cruz, realizada à zona da Estrada de Ferro Noroeste do Brasil, em novembro de 1941. *Mem Inst Oswaldo Cruz* 1942; 37(3): 259-286. <http://dx.doi.org/10.1590/S0074-02761942000300004>.

Vashetko EV, Siddikov BH. The effect of the ecology of toads on the distribution of helminths. *Türk J Zool* 1999; 23: 107-110.

Vicente JJ, Rodrigues HO, Gomes DC, Pinto RM. Nematóides do Brasil. Parte IV: Nematóides de aves. *Rev Bras Zool* 1995; 12(S1): 1-273. <http://dx.doi.org/10.1590/S0101-81751995000500001>.

Youssefi M, Hosseini SH, Esfandiari B. First report of *Hystrichis* in Eurasian Otter (*Lutra lutra*) from Iran. *Global Vet* 2010; 4(4): 422-423.