

Ascaridia pavo n. sp. (Nematoda: Ascaridida), a new species of nematode in peafowl

Ascaridia pavo n. sp. (Nematoda: Ascaridida), uma nova espécie de nematoide de pavão

Raul Henrique da Silva Pinheiro^{1*} ; Roberto Rafael de Queiroz Pereira Rodrigues² ;
Raimundo Nonato Moraes Benigno³ ; Luis Augusto Araújo dos Santos Ruffeil^{1,4} ; Elane Guerreiro Giese¹

¹Universidade Federal Rural da Amazônia – UFRA, Instituto da Saúde e Produção Animal, Laboratório de Histologia e Embriologia Animal, Belém, PA, Brasil

²Médico Veterinário autônomo, Belém, PA, Brasil

³Universidade Federal Rural da Amazônia – UFRA, Instituto da Saúde e Produção Animal, Laboratório de Parasitologia Animal, Belém, PA, Brasil

⁴Escola Estadual de Ensino Técnico do Pará Dr. Celso Malcher, Belém, PA, Brasil

How to cite: Pinheiro RHS, Rodrigues RRQP, Benigno RNM, Ruffeil LAAS, Giese EG. *Ascaridia pavo* n. sp. (Nematoda: Ascaridida), a new species of nematode in peafowl. *Rev Bras Parasitol Vet* 2026; 35(1): e011525. <https://doi.org/10.1590/S1984-29612026006>

Abstract

A new Ascaridiidae has been found parasitizing *Pavo cristatus*, an exotic bird bred on a commercial farm in the Pará Amazon. The new species of *Ascaridia* Dujardin, 1845 is described on the basis of light and scanning microscopy findings. Morphologically, the new species shares characteristics compatible with the other species of *Ascaridia* that parasitize birds in Brazil, however, the new species differs from *A. pinto* and *A. ornata* in the length and absence of a wing on the spicules, *A. hermaphrodita*, *A. serrata*, *A. columbae*, *A. galli*, *A. lineata*, *A. magalhaesi*, *A. numidae*, *A. orthocerca*, *A. pterophora* e *A. sergiomeirai* in the distribution and number of caudal papillae in males, *A. amblymorina* in the presence of a single papilla on the upper lip, associated with these characteristics most species differ in host order, with only *A. columbae*, *A. galli* and *A. lineata*, parasites of birds in the Phasianidae family. The new taxon adds morphological data to the parasitic biodiversity of commercially reared birds in Brazil.

Keywords: Taxonomy, nematode, parasite, birds, Amazon.

Resumo


Um novo Ascaridiidae foi encontrado parasitando *Pavo cristatus*, ave exótica criada em uma granja comercial na Amazônia paraense. A nova espécie de *Ascaridia* Dujardin, 1845 é descrita com base em achados de microscopia de luz e varredura. Morfologicamente, a nova espécie partilha características compatíveis com as demais espécies de *Ascaridia* que parasitam aves no Brasil, porém, a nova espécie difere de *A. pinto* e *A. ornata* no comprimento e ausência de uma asa nos espiculos, *A. hermafrodita*, *A. serrata*, *A. columbae*, *A. galli*, *A. lineata*, *A. magalhaesi*, *A. numidae*, *A. orthocerca*, *A. pterophora* e *A. sergiomeirai* na distribuição e no número de papilas caudais nos machos, *A. amblymorina* na presença de uma papila única no lábio superior, associados a essas características a maioria das espécies diferem na ordem dos hospedeiros, sendo apenas *A. columbae*, *A. galli* e *A. lineata*, parasitos de aves da família Phasianidae. O novo táxon contribuiu com adição de dados morfológicos à biodiversidade parasitária de aves criadas comercialmente no Brasil.

Palavras-chave: Taxonomia, nematoda, parasito, aves, Amazônia.

Received: August 8, 2025. Accepted: November 17, 2025.

*Corresponding author: Raul Henrique da Silva Pinheiro. Address: Avenida Presidente Tancredo Neves, 2501, Bairro Terra Firme, CEP 66077-830, Belém, PA, Brasil, Phone: +559198848-1597, e-mail: procamallanus@gmail.com. <https://orcid.org/0000-0003-3221-5017>

Assistant Editor: Estevam Guilherme Lux Hoppe



This is an Open Access article distributed under the terms of the Creative Commons Attribution License, which permits unrestricted use, distribution, and reproduction in any medium, provided the original work is properly cited.

Introduction

Brazil has a rich avifauna, and parasitological studies in its birds began with samples collected by Johann Natterer when he carried out 16 scientific expeditions in the interior of Brazil, starting in Rio de Janeiro and heading towards Mato Grosso and then to the Amazon basin, as well as Colombia and Venezuela (Goeldi, 1896; Vanzolini, 1993). Karl Asmund Rudolphi, Karl Moriz Diesing, Raffaele Molin and Anton Friedrich Schneider, when analyzing the samples collected by Natterer, described the first helminth parasites of birds in Brazil. However, the descriptions are in the main very poorly done, are composed of only a few lines and usually lack figures or drawings to support the study (Guerrero, 2021).

In 1912, Railliet & Henry proposed the creation of the subfamily Heterakinae to include the genera *Ascaridia* Dujardin, 1845; *Heterakis* Dujardin, 1845; *Subulura* Molin, 1860; *Aspidodera* Railliet & Henry, 1912 and *Cissophyllus* Railliet & Henry, 1912, morphologically identical in the presence of a pre-anal sucker, but throughout their taxonomic history the species of *Ascaridia* have been broken down into other genera, especially *Ascaris* Linnaeus, 1758 and *Heterakis* Dujardin, 1886, with the type species *Ascaridia hermaphrodita* (Froelich, 1789) Railliet & Henry, 1914, being relocated from the genus *Ascaris* (*A. hermaphrodita* Froelich, 1789) (Travassos, 1913). Morphologically, *Ascaridia* has a claviform esophagus, while *Heterakis* has an esophageal bulb, and *Ascaris* has lips with rows of denticles, a distinct characteristic of the other two genera (Anderson et al., 2009).

Ascaridia is made up of more than 50 species and has a cosmopolitan distribution. They parasitize the intestines of different types of birds, especially terrestrial species (Yamaguti, 1961; Hodová et al., 2008). In Brazil, it is represented by *Ascaridia hermaphrodita*; *Ascaridia serrata* (Schneider, 1866) Railliet & Henry, 1914; *Ascaridia amblymorpha* (Drasche, 1882) Railliet & Henry, 1914; *Ascaridia columbae* (Gmelin, 1790) Travassos, 1913; *Ascaridia galli* (Schrank, 1788) Freeborn, 1923 (Syn. *Ascaridia brasiliensis* (Magalhães, 1892)); *Ascaridia lineata* (Schneider, 1866) Railliet & Henry, 1912; *Ascaridia magalhaesi* Travassos, 1913; *Ascaridia numidae* (Leiper, 1908) Travassos, 1913; *Ascaridia ornata* Kreis, 1955; *Ascaridia orthocerca* (Stossich, 1902) Travassos, 1913; *Ascaridia pintoii* Travassos, 1933; *Ascaridia pterophora* (Creplin, 1854) Railliet & Henry, 1914 and *Ascaridia sergiomeirai* Pereira, 1933, all parasites of wild and farmed birds (Vicente et al., 1995). *Ascaridia hermaphrodita* and *A. galli* are the two most reported species (Santos et al., 2015; Tavares et al., 2017; Ramos et al., 2018), in addition to the record of an erratic cycle of *A. galli* in eggs of *Gallus gallus domesticus* (Linnaeus, 1758) (Machado et al., 2007, Bautista-Vanegas et al., 2023) and unusual hosts for the genus such as *Felis catus* Linnaeus, 1758 (Duarte, 1981; Vicente et al., 1997) and *Cerdocyon thous* Linnaeus, 1766 (Gomes, 2013; Gomes et al., 2015) in Brazil and the presence of *Ascaridia* sp. eggs in feces in dogs in some urban and rural areas of Hungary (Fok et al., 2001).

The peacock is a bird of the Phasianidae family, native to Asia, found in India, Myanmar, Java Island and the Malay Peninsula. Its geographical distribution has broadened as it has been introduced into various countries, including Brazil, where it is bred along with other domestic birds (Ramos et al. 2018). For this study, nematodes were recovered from the intestine of a specimen of *Pavo cristatus* Linnaeus, 1758 (Aves: Galliformes: Phasianidae), and subsequently studied in detail, concluding that they represent a new species, which is described here.

Material and Methods

A rural landowner with commercial breeding of *Pavo cristatus*, located in the municipality of Benevides in the state of Pará, in the Brazilian Amazon region. He obtained 12 of these birds from a cross between his breeding stock. During the first 5 months (average weight 2kg) of life, the animals were placed in a vivarium measuring 12m² wide by 2m high with a stainless-steel mesh floor raised 1.5m off the ground and isolated from other birds on the property by a screen. The water was served in automatic drinking fountains, and growth feed was provided, compatible with their age.

Two birds died, both with good body scores. The animals were submitted to necropsy on the property; the intestines were separated and fixed in 10% formalin. After these were obtained, the owner administered febendazole (Provermim®) (deworming), a packet of 20g for every 2kg of feed for 3 days in a row for the other birds, as well as sanitizing the environment.

In the laboratory, the intestine was separated and placed in Petri dishes with saline and examined using a stereomicroscope. When the intestines were examined, there were large numbers of nematodes all over the intestines, causing organ obstruction. The nematodes were removed, washed in 0.9% saline solution, quantified

and processed for light microscopy and scanning electron microscopy, following the protocol described by Pinheiro et al. (2018).

All measurements are presented in millimeters, unless otherwise indicated. Morphometric information is presented as mean, standard deviation, ranges in parentheses, and holotype and allotype measurements in square brackets. The type material was deposited in the Coleção de Invertebrados não Artrópodes at the Museu Paraense Emílio Goeldi (MPEG), municipality of Belém, State of Pará, Brazil: Type-material: Holotype male (MPEG 319), allotype female (MPEG 320) and paratypes (five females: MPEG 321; five males: MPEG 322). Zoobank Life Science Identifier: urn:lsid:zoobank.org:pub:03DF4CF4-0EE5-42D2-989F-E349BD91B23A

Results

Ascaridia Dujardin, 1844

***Ascaridia pavo* n. sp.** (Figures 1-2)

Etymology: The specific name refers to the generic name of the type host.

Description

General. Medium to large, whitish nematodes, with distinct cuticle. Lateral alae absent. Anterior extremity with 3 trilobed lips, approximately equal in size, with weak postlabial grooves and prominent lateral membranous flanges (Figures 1a, b, 2a). Dorsal lip with a pair of large double papillae; each ventral-lateral lip having one large double papilla, one small papilla and an amphid (Figure 1c, 2b). Inner surface of distal margin of each lip with several cuticular plates that form tooth-like projections at the tip. Interlabia absent. Esophagus cylindrical and slightly extended towards the posterior end without a posterior bulb (Figure 1a). Nerve-ring at about 14–39% of esophageal length. Excretory pore posterior to nerve-ring (Figure 2a, c). Ventriculus, intestinal caecum and ventricular appendix absent. Small papillae distributed randomly along the body (Figure 2a).

Males (based on 15 specimens all adult, measurements of holotype in brackets): Body length 14.00 ± 14.00 (8.00–22.00) [14.00], maximum width 0.521 ± 135.00 (0.353–0.740) [0.547] at level of esophageal-intestinal junction (Figure 1d). Dorsal and ventral-lateral lips almost equal in size, 0.111 ± 0.020 (0.083–0.137) [0.137] long, 0.163 ± 0.027 (0.127–0.190) [0.190] wide. Nerve ring and excretory pore 0.404 ± 92.00 (0.307–0.587) [0.367] and 0.509 ± 100.00 (0.413–0.693) [0.427], in lateral view respectively, from anterior extremity. Muscular esophagus 2.00 ± 0.00 (1.00–2.00) [1.00] long, 0.255 ± 66.00 (0.200–0.400) [0.240] at maximum width, representing 11% (9–15%) [9.7%] of body length. Posterior end of body curves ventrally. Ventral sucker present with smooth adhesive surface, situated at 0.435 ± 150.00 (0.173–0.633) [0.533] from cloacal aperture. Caudal papillae, 9 pairs in all, arranged as follows: 3 pairs precloacal (1st pair at the level of the sucker, 2nd pair posterior to the sucker, 3rd near the cloaca.), 4th pair para-cloacal (located laterally at level to cloaca) and 5 pairs post-cloacal; latter arranged as: 5th, 7th and 9th pairs laterally, 6th pair located subventrally and 8th pair located ventrally (Figures 1f, 2f), one pair of lateral phasmids, between the 7th and 9th pairs of post-cloacal papillae (Figure 2g). All the papillae are mammillae-shaped and arise from two circles of cuticular rings, with a knob at the tip, the 1st and 2nd pre-cloacal pairs larger than the others (Figure 2f). Medio-ventral pre-cloacal papilla and cuticular bosses absent. Spicules long, filiform, sub-equal and sclerotized 2.00 ± 0.00 (1.00–3.00) [2.00] long, representing 14% (10–21%) of total body length (Figure 1e). Gubernaculum absent. Tail 0.268 ± 51.00 (0.187–0.367) [0.240] long.

Females (based on 10 specimens all gravid with eggs, measurements of allotype in brackets): Body 17.00 ± 3.00 (14.00–24.00) [16.71] long; maximum width 0.549 ± 71.60 (0.407–0.653) [0.607]. Dorsal and ventral-lateral lips almost equal in size, 0.106 ± 0.004 (0.100–0.110) [0.100] long, 0.147 ± 0.012 (0.130–0.157) [0.155] wide. Nerve ring and excretory pore 0.345 ± 92.95 (0.260–0.507) [0.507] and 0.481 ± 72.00 (0.347–0.607) [0.580], in lateral view respectively, from anterior extremity. Muscular esophagus 2.00 ± 0.2 (1.00–2.00) [1.67] long, 0.241 ± 28.58 (0.187–0.300) [0.240] in maximum width, representing 9% (4–11%) [10%] of body length. Slitlike vulva, situated at mid-body, 9.00 ± 1.5 (8.00–13.00) [9.71] mm from anterior extremity, at 55% (53–59%) [58%] of body length (Figures 1g, 2d). Vagina muscular, directed posteriorly from vulva, vulval lips not elevated. Two uteri, one in anterior part of body, the other in posterior part. Eggs oval, unembryonated, with smooth shell, 0.064 ± 9.63 (0.048–0.087) \times 0.043 ± 7.46 (0.022–0.057) (n = 30). Rectum is a short hyaline tube; small, unicellular rectal glands are present measuring 0.333 ± 69.00 (0.200–0.407) [0.367]. Tail 0.604 ± 63.00 (0.467–0.687) [0.560] long (Figures 1h, 2e).

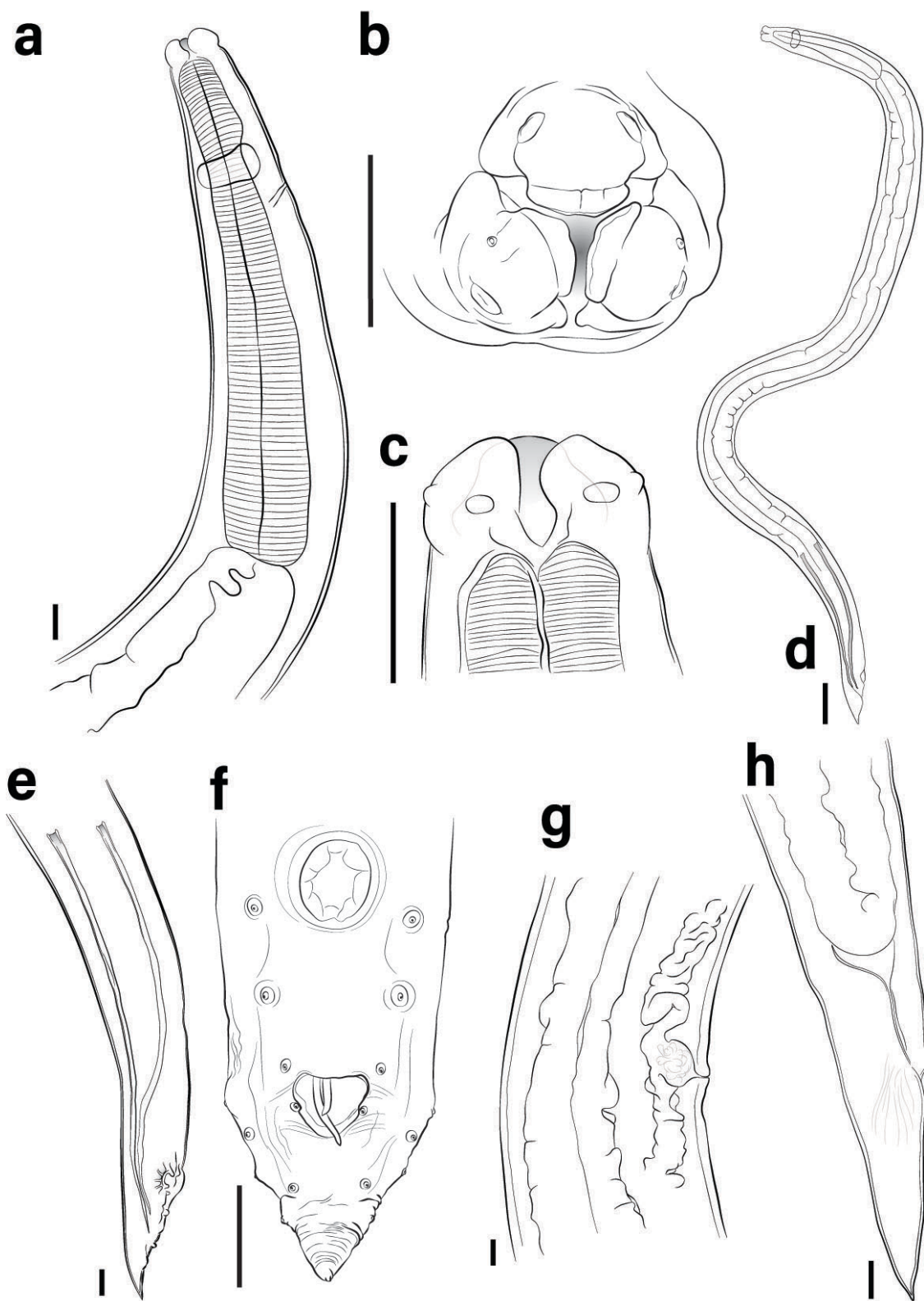


Figure 1. *Ascaridia pavo* n. sp. from *Pavo cristatus*: **(a)** Anterior extremity of female, lateral view. Scale bars = 100µm. **(b)** Cephalic region, apical view. Scale bars = 100µm. **(c)** Cephalic region of male, lateral view. Scale bars = 100µm. **(d)** Male, total length. Scale bars = 500µm. **(e, f)** Posterior end of male, lateral and ventral views, respectively. Scale bars = 100µm. **(g)** Vulva. Scale bars = 100µm. **(h)** Posterior end of female, lateral view. Scale bars = 100µm.

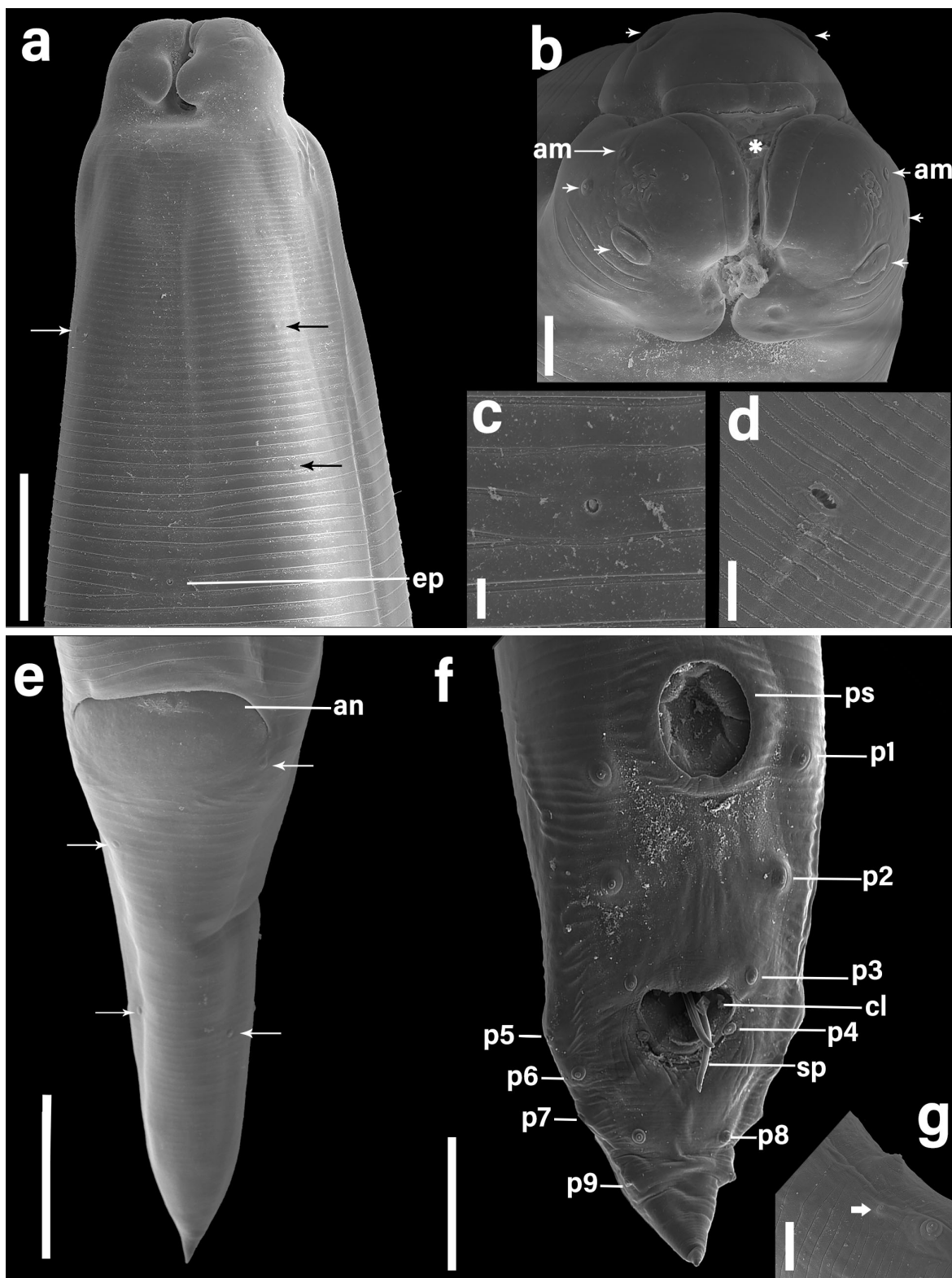


Figure 2. Scanning electron micrographs of *Ascaridia pavo* n. sp. from *Pavo cristatus*: **(a)** Cephalic region, ventral view, with excretory pore (ep) and presence of small papillae (arrow). Scale bars = 10µm. **(b)** Cephalic region, apical view, with 3 trilobed lips, with prominent lateral membranous flanges, dorsal lip with a pair of large double papillae; each of the ventral-lateral lips with a large papilla, a small papilla (arrow) and an amphid (am). Inner surface of the distal margin of each lip with a cuticular plate which at the tip forms tooth-like projections. Scale bars = 10µm. **(c)** Excretory pore. Scale bars = 20µm. **(d)** Vulva, vulval lips not elevated. Scale bars = 20µm. **(e)** Female tail, anus (an) and presence of small papillae (arrow). Scale bars = 50µm. **(f)** Tail of male, ventral views; cloacal opening, spicule, three precloacal papillae (p1, p2, p3), one pair of papillae situated paracloacally (p4), five postcloacal papillae, latter arranged as: p5, p7 and p9 pairs laterally, p6 pair located subventrally and p8 pair located ventrally. Scale bars = 100µm. **(g)** One pair of phasmids lateral. Scale bars = 20µm.

Discussion

From the descriptions of *Ascaridia* species, it was evident that many morphological features were no longer present. The most effective strategies for grouping and comparing species proved to be the host group parasitized by the species (mainly at the host order level); intraspecific variability, probably resulting from the presence of the parasites in different hosts; the intensity of infection; and geographical location (Zhao et al., 2016). With that in mind, to avoid describing a species that might be synonymized in the future, in this paper we will compare the new taxon with all the known species of the genus in Brazil.

In Brazil, 13 species of *Ascaridia* have been recorded parasitizing different groups of birds (Vicente et al., 1995). *Ascaridia pavo* n. sp. has 9 pairs of caudal papillae, which makes it directly different from *A. hermafrodita*; *A. serrata*; *A. columbae*; *A. galli*; *A. lineata*; *A. magalhaesi*; *A. numidae*; *A. orthocerca*; *A. pterophora* and *A. sergiomeirai* since they all have the same or more than 10 pairs of caudal papillae. *Ascaridia amblymorpha* has 9 pairs of caudal papillae but differs from the new taxon by the presence of an odd papilla on the upper lip, a feature absent in *Ascaridia pavo* n. sp. Additionally, *A. hermaphrodita*, *A. galli*, *A. columbae*, *A. magalhaesi*, *A. ornata*, *A. sergiomeirai* have cervical alae, which does not occur in the new species.

Ascaridia pavo n. sp. has large spicules (1–3 mm), compared to *A. serrata*, *A. pinto*, *A. pterophora* and *A. sergiomeirai*, which have spicules smaller than 1 mm (0.86–0.93 mm, 0.14 mm, 0.72–0.86 mm and 0.90–0.94 mm respectively). *Ascaridia columbae*, *A. hermaphrodita*, *A. ornata* and *A. sergiomeirai* have spicular alae, a feature that is absent in the new species.

The males of the new species have a smaller body size (8–12mm), which distinguishes them different from the others. As an example, *A. serrata* and *A. galli* are 5 to 6 times larger than *Ascaridia pavo* n. sp. Morphometric comparisons between the descriptions of *Ascaridia pavo* n. sp. are shown in Table 1, including the additional data presented in this study. Morphologically, there are few studies characterizing *Ascaridia* species, and the pathogenicity to the host (Ramos et al., 2018; Mubarakah et al., 2019; Torres et al., 2019; AL-Quraishi et al., 2020; Shohana et al., 2023).

Table 1. Comparison of morphometric characteristics of males *Ascaridia pavo* n. sp. with other species of *Ascaridia* in Brazil. (dimensions in mm).

Caracteres	<i>Ascaridia pavo</i> n. sp.	<i>A. magalhaesi</i>	<i>A. pinto</i>	<i>A. galli</i>	<i>A. lineata</i>	<i>A. hermafrodita</i>
	Male	Male	Male	Male	Male	Male
Length ^a	8–12	30	28	30–80	55–68	26–46
Width	0.353–0.740	1.46	0.7	0.971–1.26 ^c	0.90	1.2–1.4
Cervical ala	Absent	Present	Not determined	Present	Not determined	Present
Muscular esophagus (length)	1–2	–	1.38	1.67–3.26 ^c	–	1.5–2.1
Number of pairs of caudal papillae	9	12	9	10	10	15–16
Precloacal papillae ^b	3ve	5	–	3 ^c	3 ^d	5
Adcloacal papillae ^b	1ve	4	–	1ve ^c	–	1–2
Postcloacal papillae ^b	5 (1ve+1sl+3L)	3	–	6 ^c (1sv+2ve+3L)	7 ^e	7–8
Spicule (length)	1–3	1.66	0.14	4	1.6–2.4	2.30–2.93
Spicular alae	Absent	Not determined	Not determined	Absent	Not determined	Present
Reference	Present study	Travassos (1913)	Travassos (1933)	Cram (1927) Zhao et al. (2016)	Cram (1927)	Travassos (1930)

^aMeasurements in millimeters unless indicate; ^bAbbreviations: ve= ventral papillae, sl= sublateral papillae, L= lateral papillae, 1ph = pairs of phasmids, u= unpaired papillae; ^cbased on Zhao et al. (2016); ^dbased on Travassos (1913); ^ebased on Pinto et al. (1991); ^fbased on Santos et al. (2025).

Table 1. Continued...

Caracteres	<i>Ascaridia pavo</i> n. sp.	<i>A. serrata</i>	<i>A. amblymorina</i>	<i>A. orthocerca</i>	<i>A. numidae</i>	<i>A. columbae</i>
	Male	Male	Male	Male	Male	Male
Length ^a	8–22	46–60	40	30–40	19.4–35	16–31
Width	0.353–0.740	1.21–1.22	1.25	1–2	0.72–0.88	1.1
Cervical ala	Absent	Present	Not determined	Not determined	Not determined	Present
Muscular esophagus (length)	1–2	2.37–2.63	–	–	–	–
Number of pairs of caudal papillae	9	10	9	11	10	12–13 ^f
Precloacal papillae ^b	3ve	3	3+1u	5	3	5 ^f –7
Adcloacal papillae ^b	1ve	1	–	–	–	–
Postcloacal papillae ^b	5 (1ve+1sl+3L)	6	6	6	7	5–8 ^f
Spicule (length)	1–3	0.86–0.93	–	–	3	1.2–1.9
Spicular alae	Absent	Not determined	Not determined	Not determined	Not determined	Present
Reference	Present study	Proença (1937)		Vicente et al. (1995)		Travassos (1913)

Caracteres	<i>Ascaridia pavo</i> n. sp.	<i>A. sergiomeirai</i>	<i>A. ornata</i>	<i>A. pterophora</i>
	Male	Male	Male	Male
Length ^a	8–12	27–30	27–31	30.45–36.30
Width	0.353–0.740	0.60–0.68	0.69–0.80	0.59–0.72
Cervical ala	Absent	Present	Present	Not determined
Muscular esophagus (length)	1–2	0.7–1.9	–	2.27–2.83
Number of pairs of caudal papillae	9	10	9	12
Precloacal papillae ^b	3ve	7	–	5
Adcloacal papillae ^b	1ve	–	–	–
Postcloacal papillae ^b	5 (1ve+1sl+3L)	3	–	7
Spicule (length)	1–3	0.90–0.94	1.93–2.73	0.72–0.86
Spicular alae	Absent	Present	Present	Not determined
Reference	Present study	Pereira (1933)	Kajerova et al. (2004)	Christofaro & Feijó (1976)

^aMeasurements in millimeters unless indicate; ^bAbbreviations: ve= ventral papillae, sl= sublateral papillae, L= lateral papillae, 1ph = pairs of phasmids, u= unpaired papillae; ^cbased on Zhao et al. (2016); ^dbased on Travassos (1913); ^ebased on Pinto et al. (1991); ^fbased on Santos et al. (2025).

The new species adds to the biodiversity of *Ascaridia* parasites of birds in the Phasianidae family. Zhao et al. (2016), recorded parasitism by *A. galli* in *Pavo muticus* in Xuanwuhu Zoo, Nanjing, Jiangsu Province, China. Yamaguti (1961) recorded the occurrence of *A. galli* in *Phasianus colchicus formosanus* in Japan. Additionally, this species has been recorded in different countries parasitizing *Gallus gallus* (Ackert 1931; Mozgovi 1953; Ramadan & Znada, 1992). In Brazil, Teixeira et al. (2012) and Ramos et al. (2018) recorded the occurrence of *A. galli* in *Pavo cristatus* in the states of Bahia and Goiás respectively, using morphological and macroscopic analyses and clinical signs of the animals for diagnosis. Adding to the records of *Ascaridia* in the national territory, Vicente et al. (1995) recorded *A. columbae*, *A. galli* and *A. lineata* parasitizing *Gallus gallus* var. *domesticus* (Linnaeus, 1758) in the states of Rio de Janeiro, Rondônia, Bahia, Ceará, Maranhão, Mato Grosso, Mato Grosso do Sul, Minas Gerais, Pará, Paraná, Pernambuco, Piauí, Rio Grande do Sul, São Paulo, Santa Catarina and the Federal District and *A. galli* in *Meleagris gallopavo* Linnaeus, 1758 in Goiás, Paraná, Pernambuco and the Federal District. The same authors recorded *A. hermaphrodita*, *A. ornata* and *A. columbae* parasitizing birds in the states of Pará and Amapá, the same biogeographical region as the new taxon.

Acknowledgments

The authors are grateful to the Laboratório de Histologia e Embriologia Animal and Laboratório de Microscopia Eletrônica de Varredura – Instituto da Saúde e Produção Animal – Universidade Federal Rural da Amazônia – UFRA, campus Belém, State of Pará, Brazil for the use of the scanning electron microscope.

Financial Support

Dra. Elane Giese was supported by a research fellowship from the Conselho Nacional de Pesquisa e Desenvolvimento Tecnológico (CNPq-Brasil) (#304593-2023-0). Dr. Raul Henrique da Silva Pinheiro was supported by a Post-doctoral researcher fellowship of the Conselho Nacional de Pesquisa e Desenvolvimento Tecnológico (CNPq, Brasil) (#171021/2023-1), developed at the Laboratório de Histologia e Embriologia Animal of Universidade Federal Rural da Amazônia (Pará, Brazil).

Data availability

Data will be made available on request.

Ethics declaration

All applicable institutional, national, and international guidelines for animal care and use were followed. The nematodes used in this study were donated by veterinarian and owner of Sítio Pereira, Mr. Roberto Rafael de Queiroz Pereira Rodrigues. We present the Biological Material Donation Agreement, a model used by LHEA for receiving biological material. The receipt of biological material from different types of birds is covered by the Animal Use Ethics Committee of the Federal Rural University of Amazonia (CEUA/UFRA) (under license number 7809140122).

Conflict of interest

The authors declare that they have no conflict of interest.

Author contributions

Raul Henrique da Silva Pinheiro and Roberto Rafael de Queiroz Pereira Rodrigues conceived and designed the study. Raimundo Nonato Moraes Benigno and Luis Augusto Araújo dos Santos Ruffeil collected the samples and performed the laboratory analysis. Raul Henrique da Silva Pinheiro and Luis Augusto Araújo dos Santos Ruffeil drafted the manuscript and analyzed the data. Elane Guerreiro Giese drafted the manuscript. All authors reviewed and approved the final version of the manuscript.

References

- AL-Quraishi MA, Al-Musawi HS, AL-Haboobi ZAM. Pathological study of *Ascaridia galli* in poultry. *Eurasia J Biosci* 2020; 14(2): 3327-3329.
- Anderson RC, Chabaud AG, Wilmott S. *Keys to the Nematode Parasites of Vertebrates: archival volume*. Cambridge: Cabi; 2009. <https://doi.org/10.1079/9781845935726.0000>.
- Bautista-Vanegas AL, Esteban-Mendoza MV, Cala-Delgado DL. *Ascaridia galli*: a report of erratic migration in eggs for human consumption in Bucaramanga, Colombia – case report. *Arq Bras Med Vet Zootec* 2023; 75(1): 122-126. <https://doi.org/10.1590/1678-4162-12818>.
- Cram EB. Bird parasites of the nematode suborders Strongylata, Ascaridata, and Spirurata. *U S Natl Mus Bull* 1927; 140, 1-465.
- Cristofaro R, Feijó LMF. Contribuição ao estudo da fauna helmintológica do Estado Mato Grosso. *Atas Soc Biol Rio de Janeiro* 1976; 18: 53-57.
- Duarte MJF. Helmintos parasitas de animais domésticos do Estado do Rio de Janeiro. *Arq Esc Sup Vet Univ Fed Minas Gerais* 1981; 33(1): 67-98.
- Fok E, Szatmári V, Busák K, Rozgonyi F. Prevalence of intestinal parasites in dogs in some urban and rural areas of Hungary. *Vet Q* 2001; 23(2): 96-98. <https://doi.org/10.1080/01652176.2001.9695091>. PMID:11361108.
- Goeldi E. Johannes von Natterer. *Bol Mus Paraense Hist Nat Ethnogr* 1896; 1(1/4): 189-217.
- Gomes APN, Olifiers N, Santos MM, Simões RO, Maldonado A Jr. New records of three species of nematodes in *Cercocyon thous* from the Brazilian Pantanal wetlands. *Rev Bras Parasitol Vet* 2015; 24(3): 324-330. <https://doi.org/10.1590/S1984-29612015061>. PMID:26444063.
- Gomes APN. *Análise morfológica e ecológica de helmintos parasitos gastrointestinais de cachorro-do-mato (Cercocyon thous Linnaeus, 1766) do Pantanal do Mato Grosso do Sul* [dissertação]. Rio de Janeiro: Instituto Oswaldo Cruz; 2013.
- Guerrero R. Natterer in Neotropical Nematoda: Species Described by Rudolphi, Diesing, and Molin. *MANTER: J Parasite Biodivers* 2021; 17: 1-54. <https://doi.org/10.32873/unl.dc.manter17>.
- Hodová I, Baruš V, Tukač V. Note on morphology of two nematode species *Ascaridia hermaphrodita* and *Ascaridia platyceri* (Nematoda): scanning electron microscope study. *Helminthologia* 2008; 45(3): 109-113. <https://doi.org/10.2478/s11687-008-0021-4>.
- Kajerova V, Baruš V, Literak I. Nematodes from the genus *Ascaridia* parasitizing psittaciform birds: a review and determination key. *Vet Med (Praha)* 2004; 49(6): 217-223. <https://doi.org/10.17221/5698-VETMED>.
- Machado HHS, Lemos LS, Almeida LG, Mattos DG Jr. Nota científica: ciclo errático de *Ascaridia galli* (Schrank, 1788) em ovo de galinha. *Cienc Anim Bras* 2007 [cited 2025 Aug 8];8(1): 147-149. Available from: <https://revistas.ufg.br/vet/article/view/1166>
- Mubarakah WW, Nurcahyo W, Prastowo J, Kurniasih K. In vitro and in vivo *Areca catechu* crude aqueous extract as an anthelmintic against *Ascaridia galli* infection in chickens. *Vet World* 2019; 12(6): 877-882. <https://doi.org/10.14202/vetworld.2019.877-882>. PMID:31440008.
- Pereira C. Novo nematoide parasito de psitacideos. *Rev Med Cirurg Brasil* 1933; 41: 7-10.
- Pinheiro RHS, Melo FTV, Monks S, Santos JN, Giese EG. A new species of *Procamallanus* Baylis, 1923 (Nematoda, Camallanidae) from *Astronotus ocellatus* (Agassiz, 1831) (Perciformes, Cichlidae) in Brazil. *ZooKeys* 2018; 790(790): 21-33. <https://doi.org/10.3897/zookeys.790.24745>. PMID:30364795.
- Pinto RM, Vicente JJ, Noronha D, Fábio SP. New records for the nematodes *Ascaridia columbae* (Gmelin) Travassos, *Acuaria mayori* Lent, Freitas & Proença and *Aproctella stoddardi* Cram in Brazilian birds, with redescription of the species. *Rev Bras Zoo* 1991; 8(1-4): 1-6. <https://doi.org/10.1590/S0101-81751991000100001>.
- Proença MC. Redescrição de *Ascaridia serrata* (Schneider, 1866) Railliet & Henry 1914: (Nematoda: Ascaroidea). *Mem Inst Oswaldo Cruz* 1937; 32(1): 101-103. <https://doi.org/10.1590/S0074-02761937000100010>.
- Ramos DGS, Silva APJ, Abreu RR, Wessel ACR, Dias NG, Oliveira IB, et al. Ocorrência e lesões causadas por ascarídeos em *Pavo cristatus* (Phasianidae) de criatório não comercial em Jataí, Goiás. *Braz J Anim Environ Res* 2018; 1(2): 268-275.
- Santos OAS, Kanaan V, Rocha HLS, Silva RJ, Raso TF. *Ascaridia hermaphrodita* (Froelich, 1789) and *Ascaridia columbae* (Gmelin, 1780) in neotropical psittacine birds. *Rev Bras Parasitol Vet* 2025; 34(2): e022224. <https://doi.org/10.1590/s1984-29612025015>. PMID:40266047.
- Santos PMS, Silva SGN, Fonseca CF, Oliveira JB. Parasites of birds and mammals in captivity in Pernambuco state, Brazil. *Pesq Vet Bras* 2015; 35(9): 788-794. <https://doi.org/10.1590/S0100-736X2015000900004>.
- Shohana NN, Rony SA, Ali MH, Hossain MS, Labony SS, Dey AR, et al. Anisuzzaman. *Ascaridia galli* infection in chicken: pathobiology and immunological orchestra. *Immun Inflamm Dis* 2023; 11(9): e1001. <https://doi.org/10.1002/iid3.1001>. PMID:37773698.

- Tavares LER, Campião KM, Costa-Pereira R, Paiva F. Helminthos endoparasitos de vertebrados silvestres em Mato Grosso do Sul, Brasil. *Iheringia Ser Zool* 2017; 107(Supl): e2017106. <https://doi.org/10.1590/1678-4766e2017106>.
- Teixeira M, Monteiro JP, Catenacci LS, Azevedo Rodrigues MD, Carvalho M. Ascariasis in peafowl *Pavo cristatus* (Phasianidae) due to *Ascaridia galli* Schrank, 1788. *J Zoo Wildl Med* 2012; 43(3): 585-587. <https://doi.org/10.1638/2011-0122R2.1>. PMID:23082523.
- Torres ACD, Costa CS, Pinto PN, Santos HA, Amarante AF, Gómez SYM, et al. An outbreak of intestinal obstruction by *Ascaridia Gallii* in broilers in Minas Gerais. *Braz J Poult Sci* 2019; 21(4): 10-13. <https://doi.org/10.1590/1806-9061-2019-1072>.
- Travassos L. *Ascaridia pinto* n. sp. parasite ele la perdix. *C R Soe Biol* 1933; 112: 1475.
- Travassos L. Fauna helmintológica dos "Psitacidae" do Brasil. *Arq Inst Biol (Sao Paulo)* 1930; 3: 5-20.
- Travassos L. Sobre as espécies brasileiras da subfamília Heterakinae Railliet & Henry. *Mem Inst Oswaldo Cruz* 1913; 5(3): 271-318. <https://doi.org/10.1590/S0074-02761913000300005>.
- Vanzolini PE. As viagens de Johann Natterer no Brasil, 1817-1835. *Pap Avulsos Zool* 1993; 38(3): 17-60.
- Vicente JJ, Rodrigues HO, Gomes DC, Pinto RM. Nematóides do Brasil. Parte IV: nematóides de aves. *Rev Bras Zool* 1995; 12(Supl 1): 1-273. <https://doi.org/10.1590/S0101-81751995000500001>.
- Vicente JJ, Rodrigues HO, Gomes DC, Pinto RM. Nematóides do Brasil. Parte V: nematóides de mamíferos. *Rev Bras Zool* 1997; 14(Supl 1): 1-452. <https://doi.org/10.1590/S0101-81751997000500001>.
- Yamaguti S. *Systema Helminthum*. 3. *The nematodes of vertebrates*. New York: Intersci. Publ.; 1961. 1261 p.
- Zhao WT, Guo YN, Zhang LP, Li L. Ultrastructure of *Ascaridia galli* (Schrank, 1788) (Nematoda: Ascaridida) from the endangered green peafowl *Pavo muticus* Linneatus (Galliformes: Phasianidae). *Acta Parasitol* 2016; 61(1): 66-73. <https://doi.org/10.1515/ap-2016-0007>. PMID:26751873.